



Le lambeau antébrachial

*Une technique de reconstruction
avec microchirurgie dans les
tumeurs de la tête et du cou*

CERUTTI Valérie MARCHESI Nathalie

ALIBODE

2016



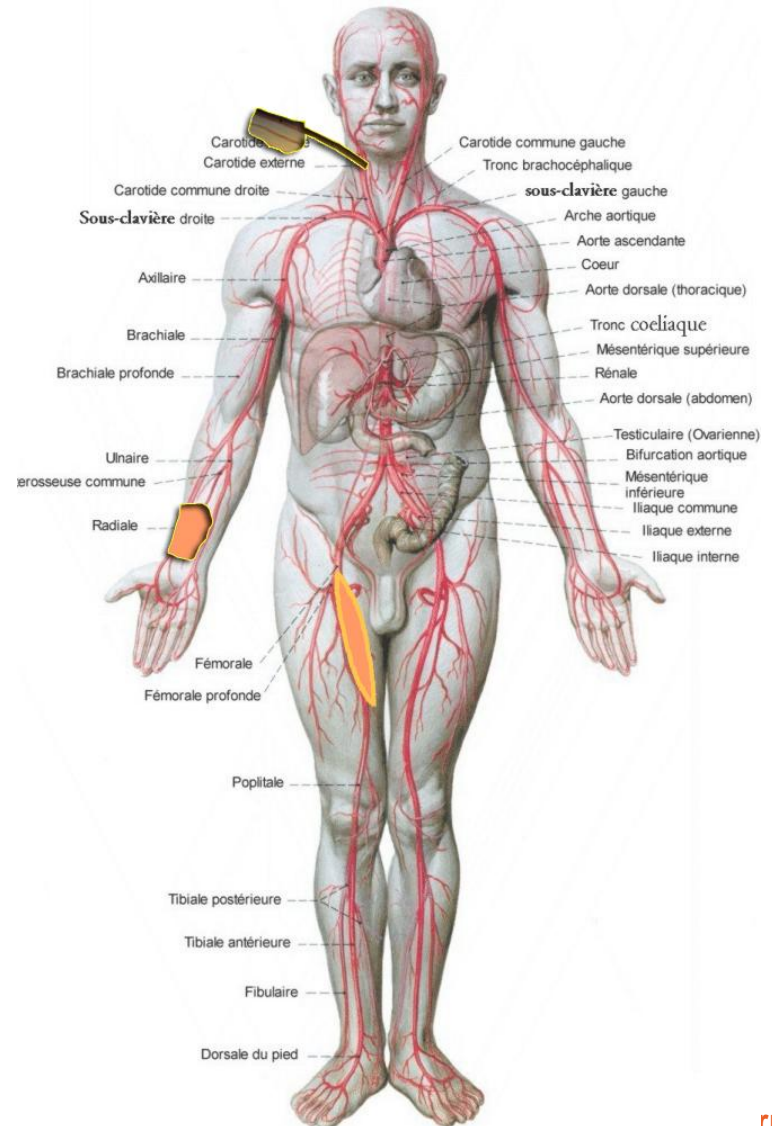
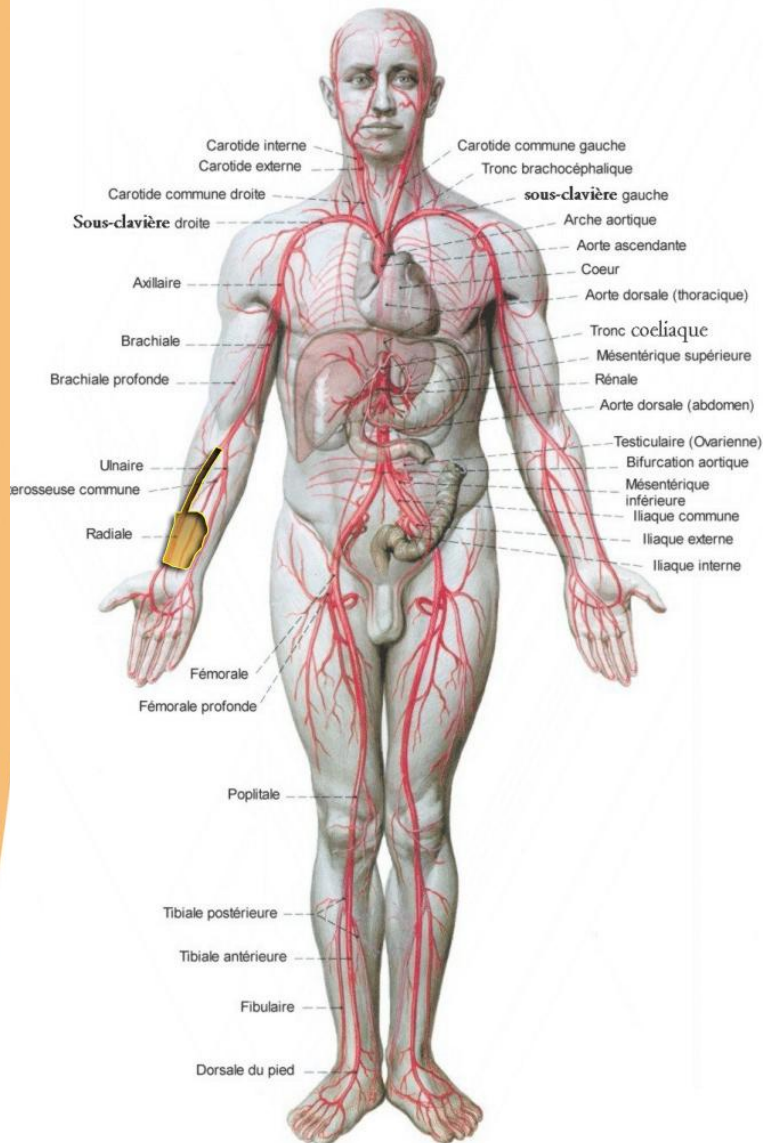
**Institut
de Cancérologie
de Lorraine**

Alexis Vautrin

Ensemble, construisons l'avenir

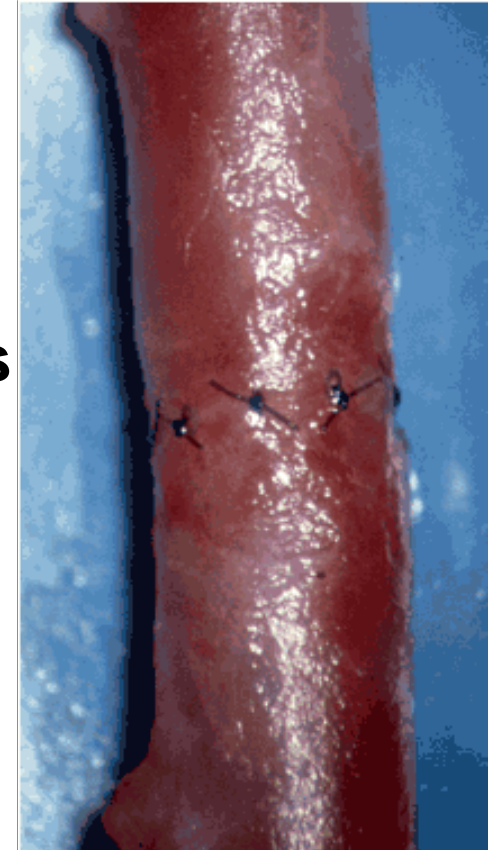


Le Lambeau et La Greffe



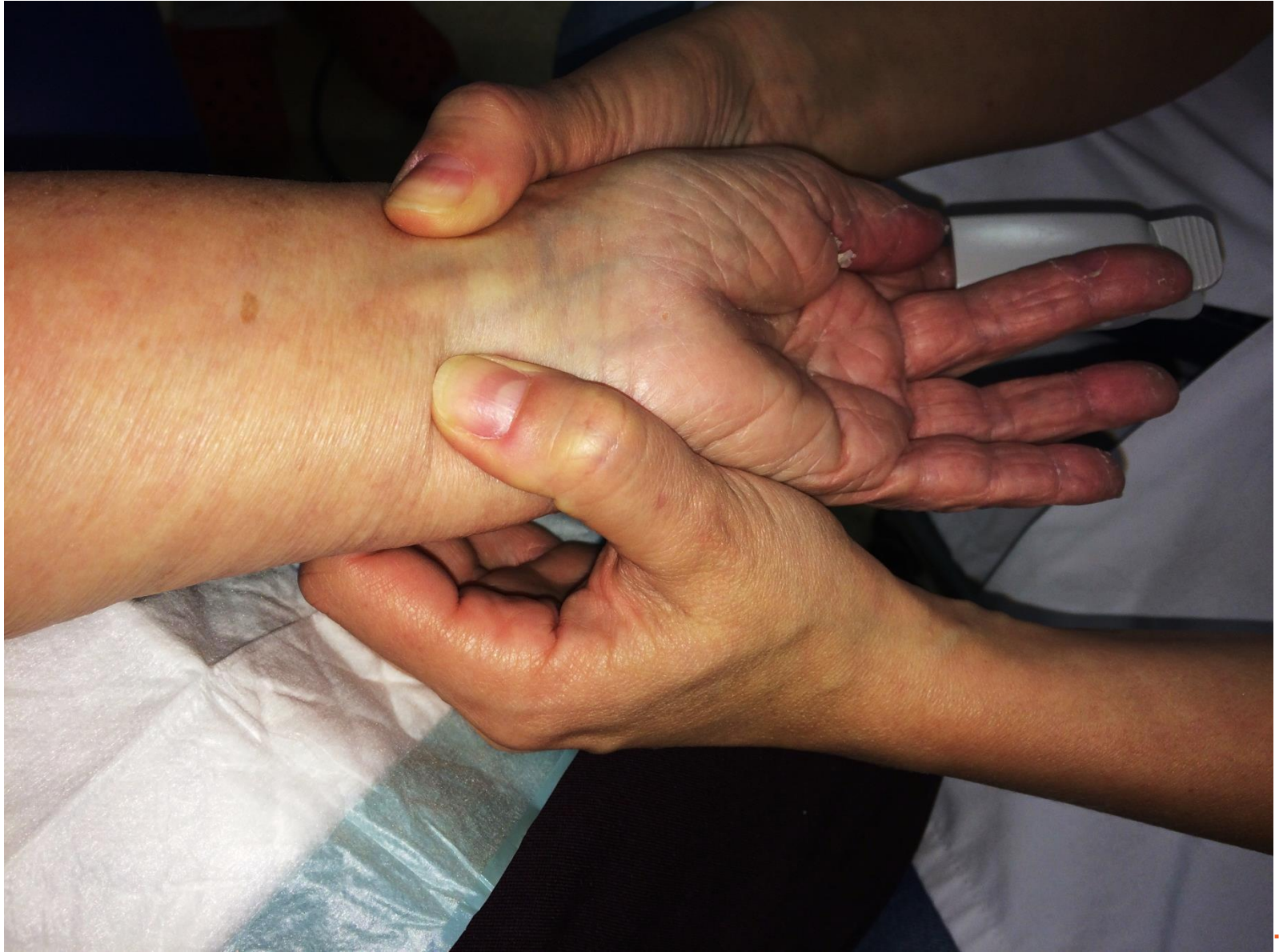- **Liés au patient**
 - **Etat nutritionnel**
 - **Facteurs de risques**
 - **Hygiène bucco-dentaire**
 - **Antécédents cardiovasculaires**

- **Institutionnels**



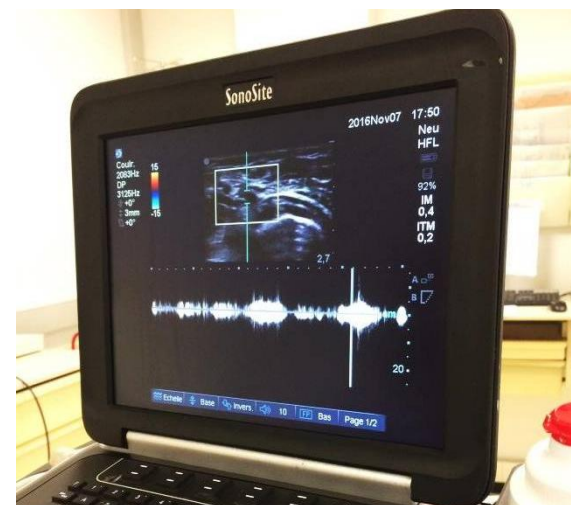
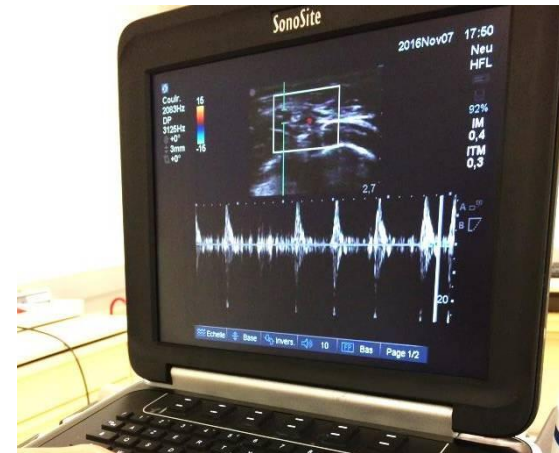
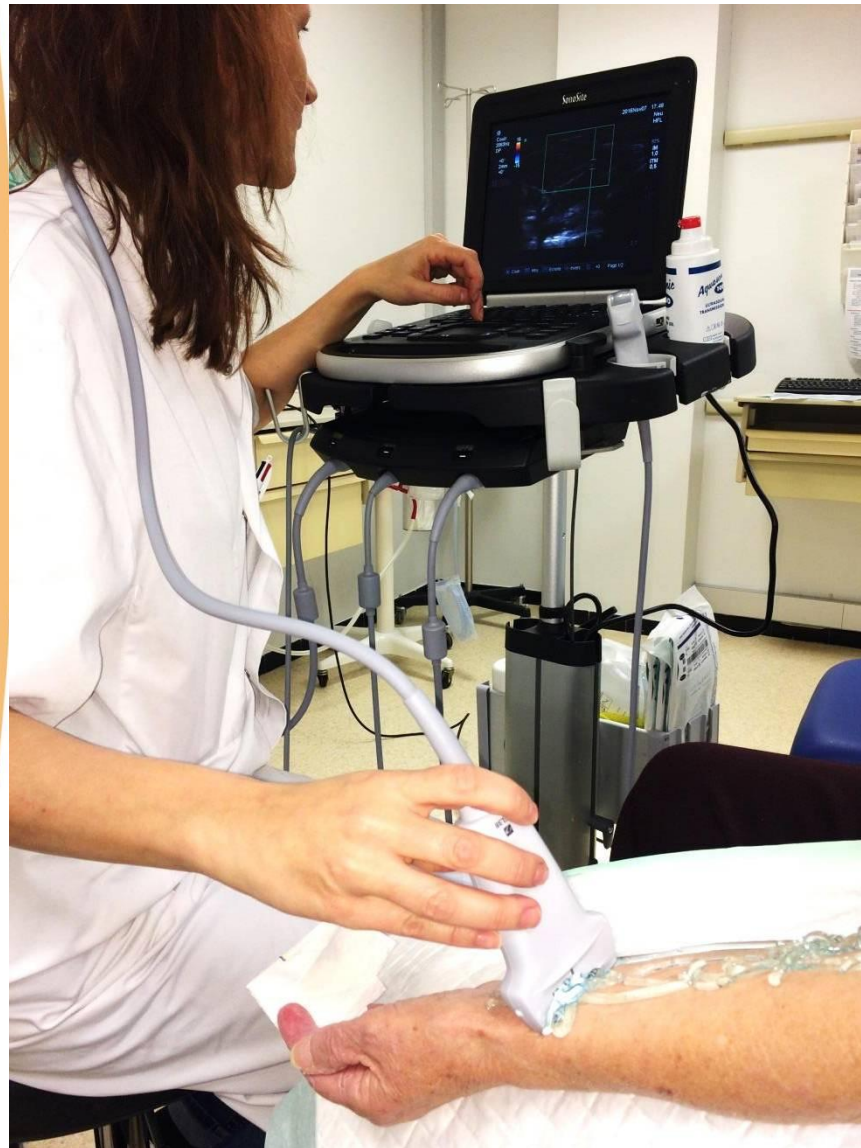


Examens pré-op : Test d'Allen



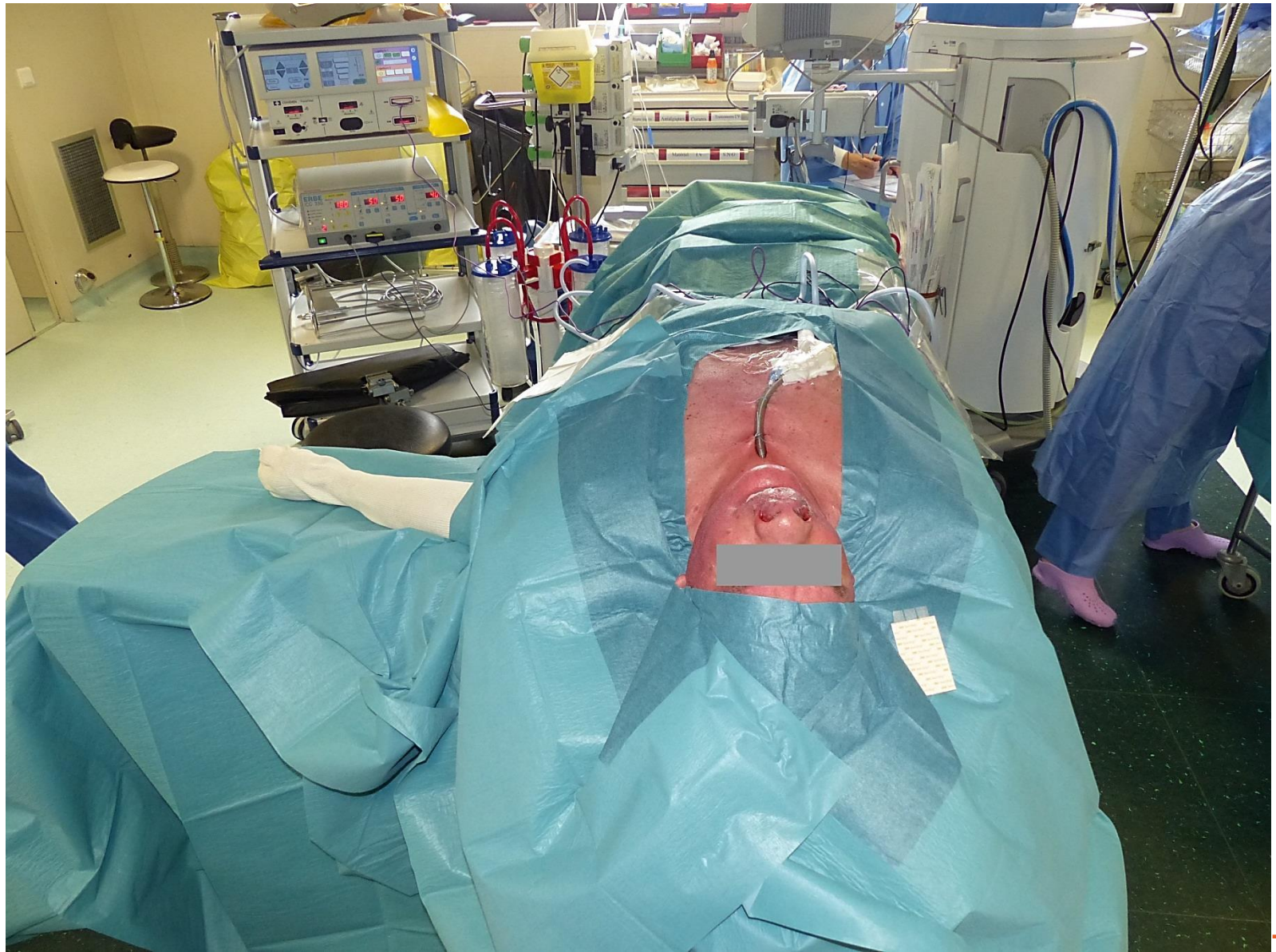

Examens pré-op : Echo doppler



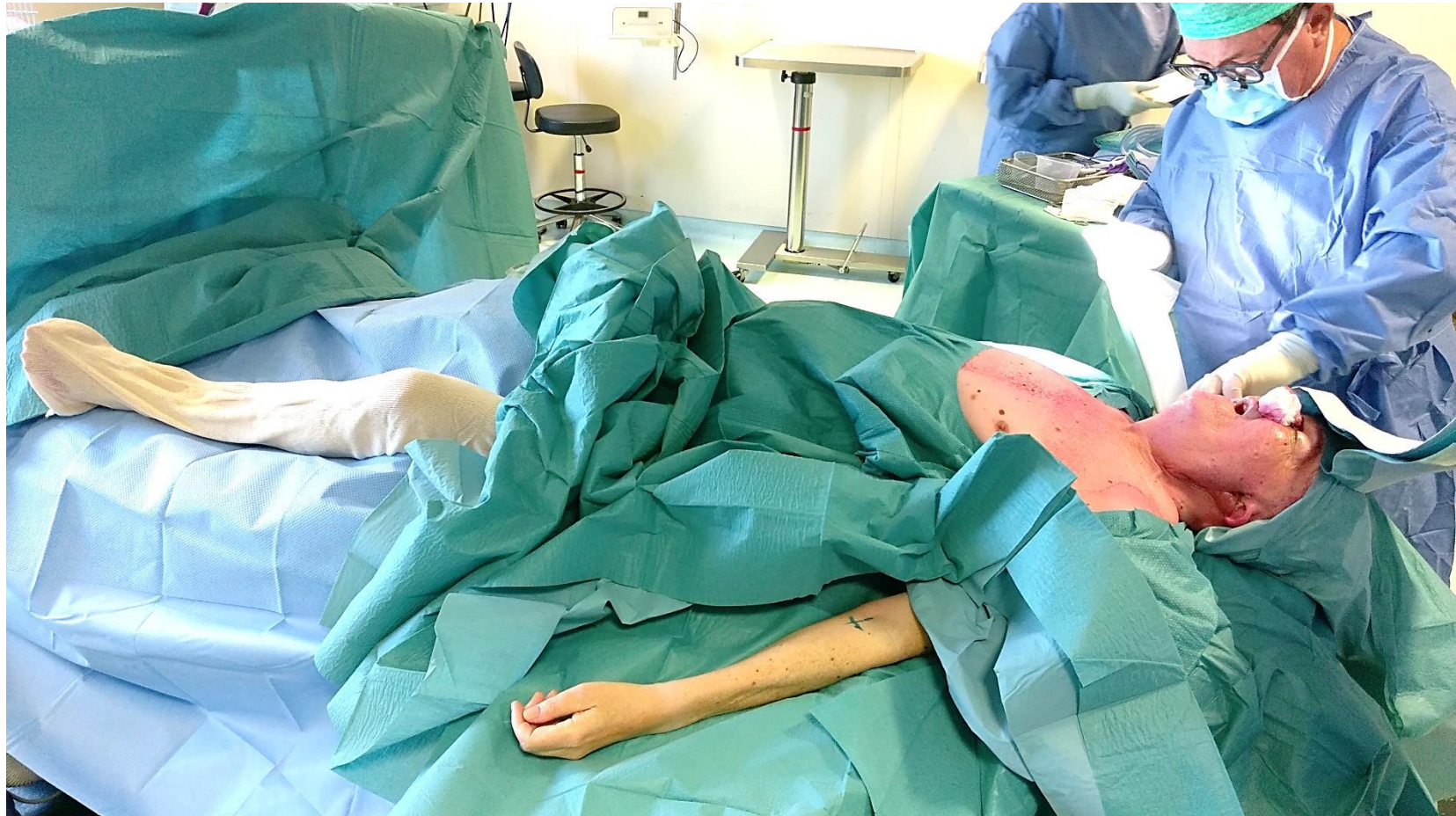

Equipement patient



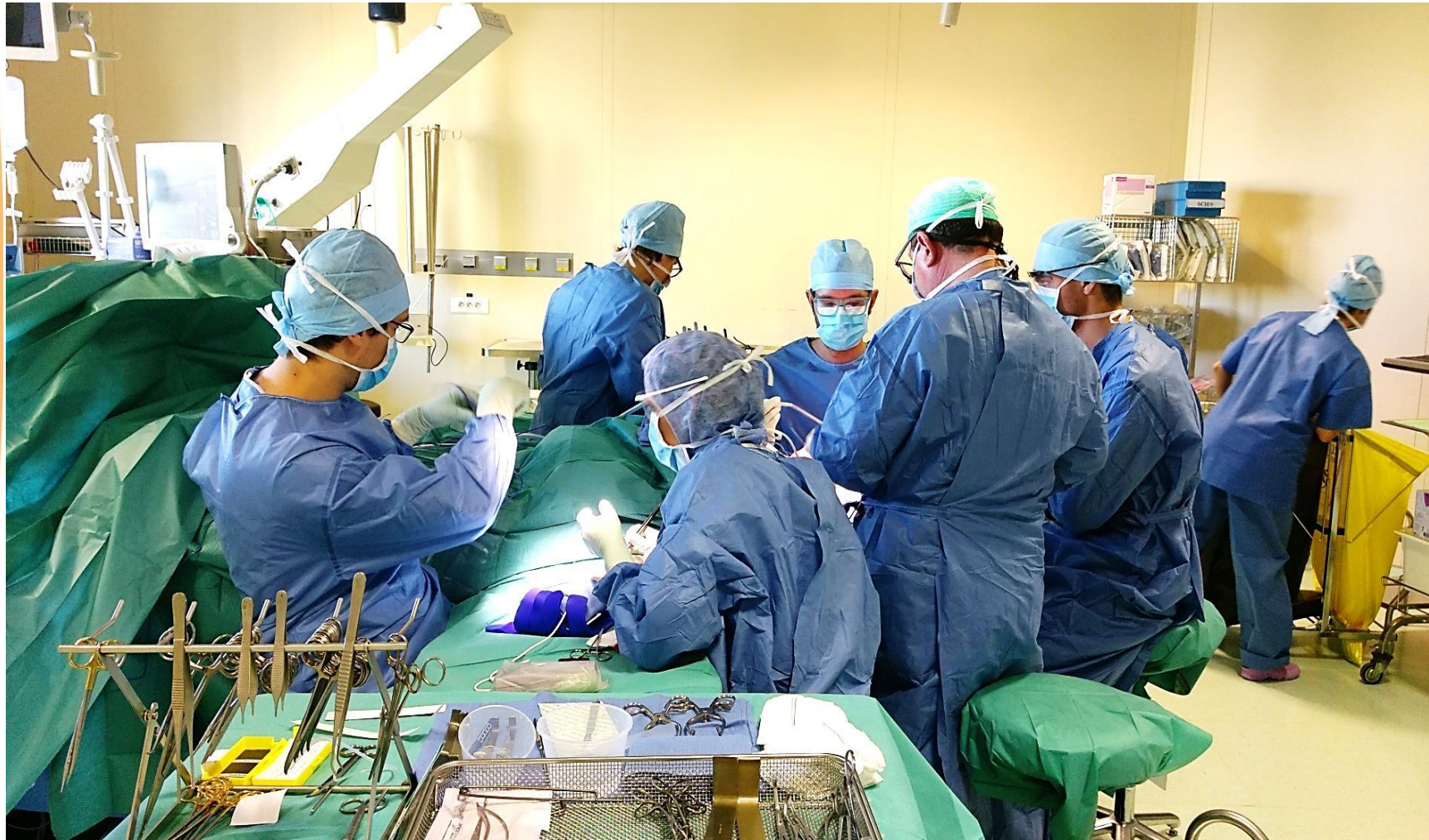

Champagne

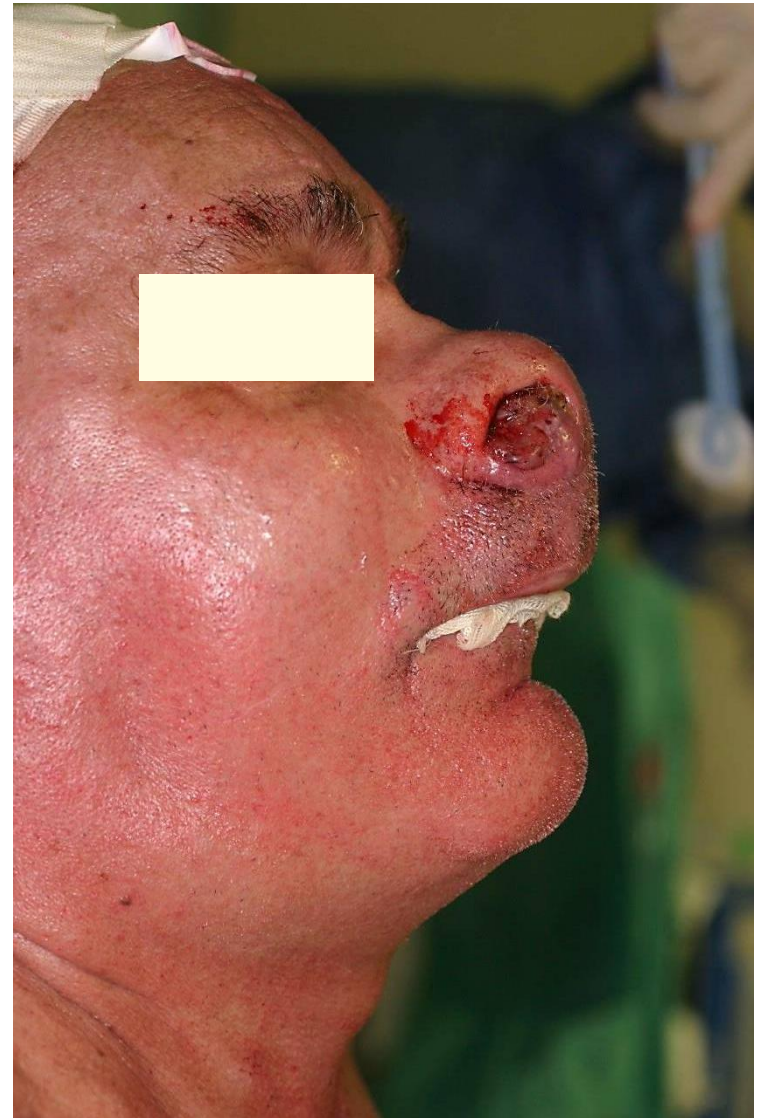
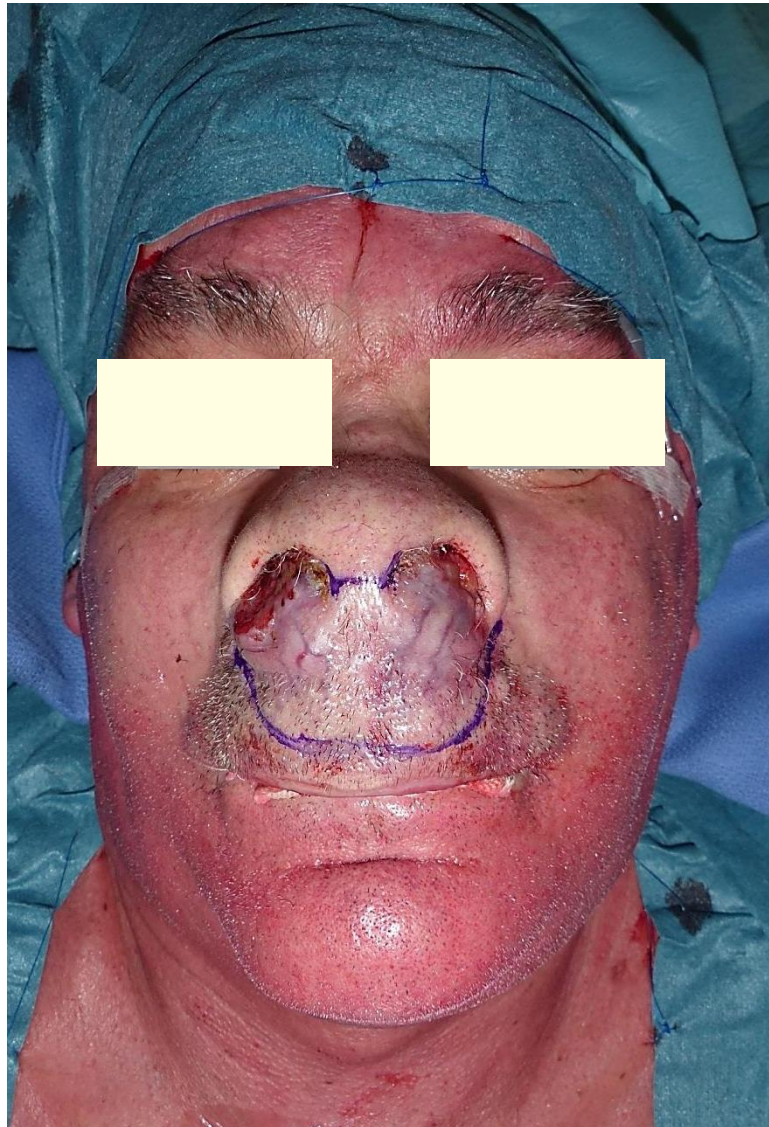


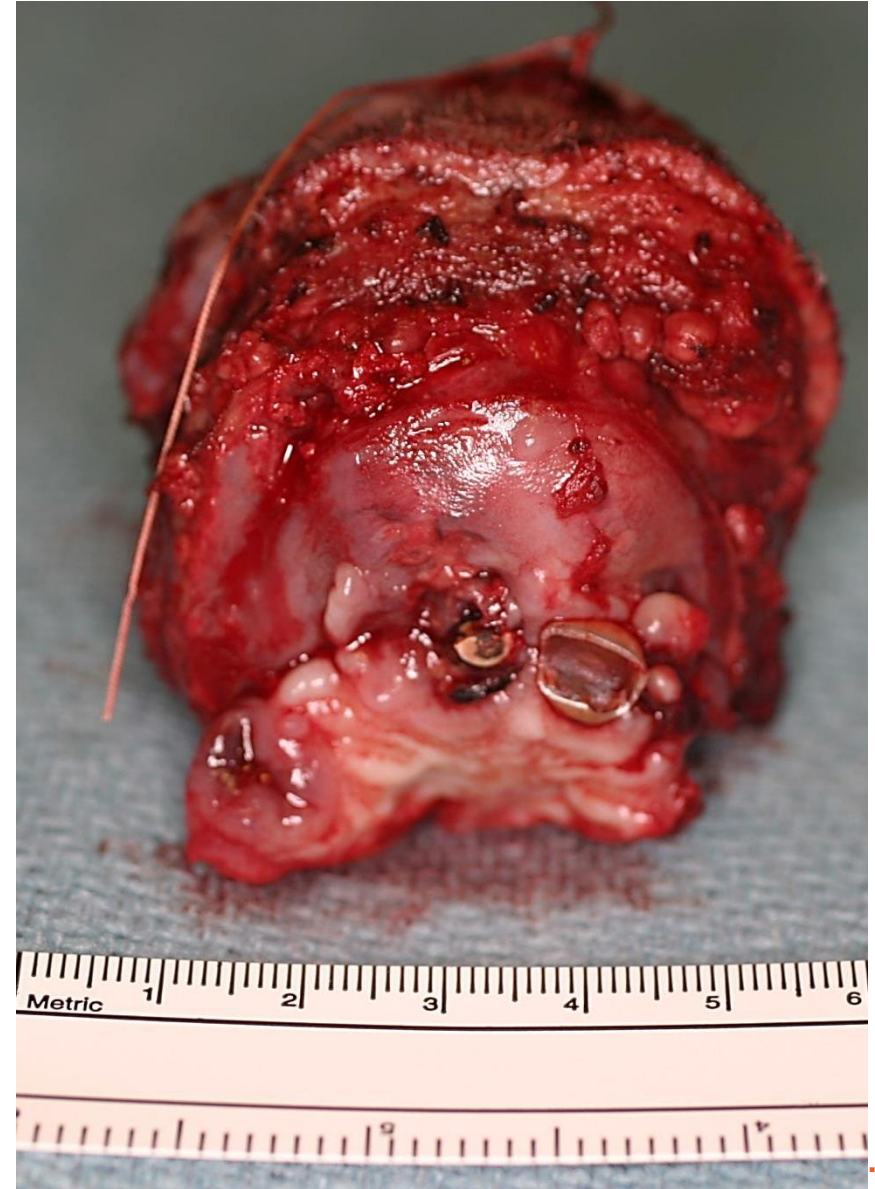
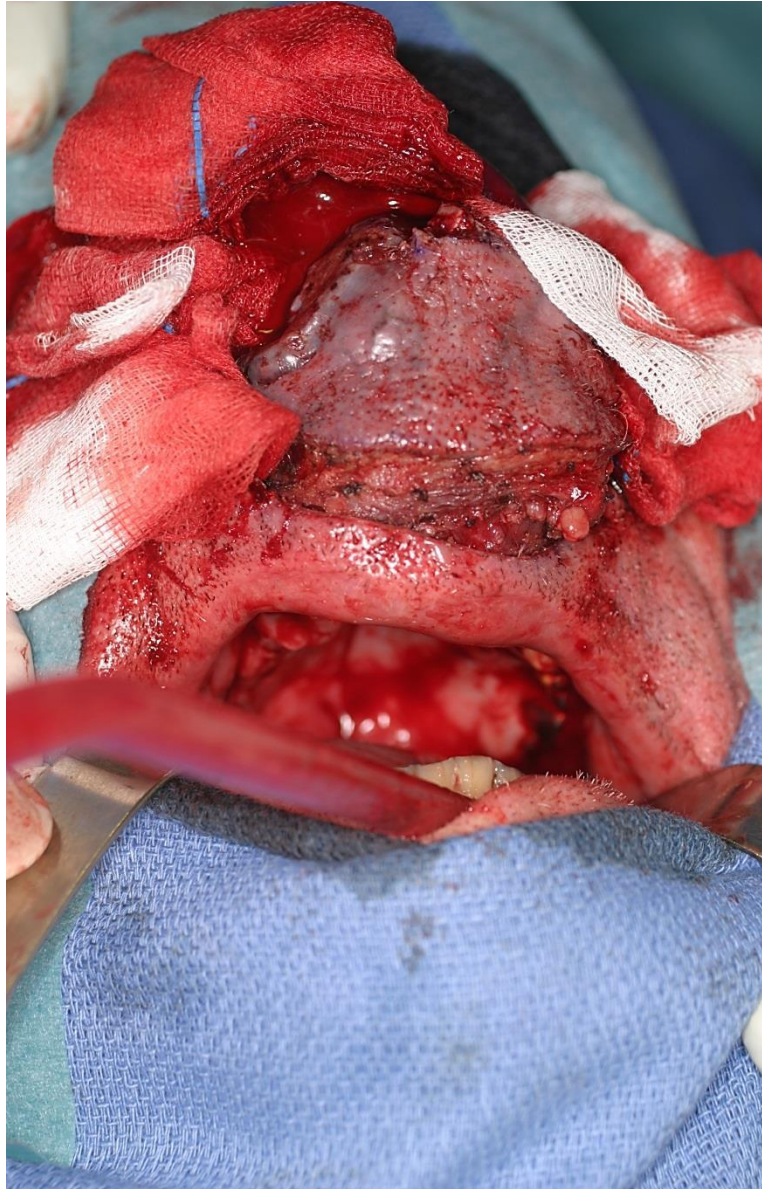
Double équipe



Exérèse tumeur cloison nasale T4

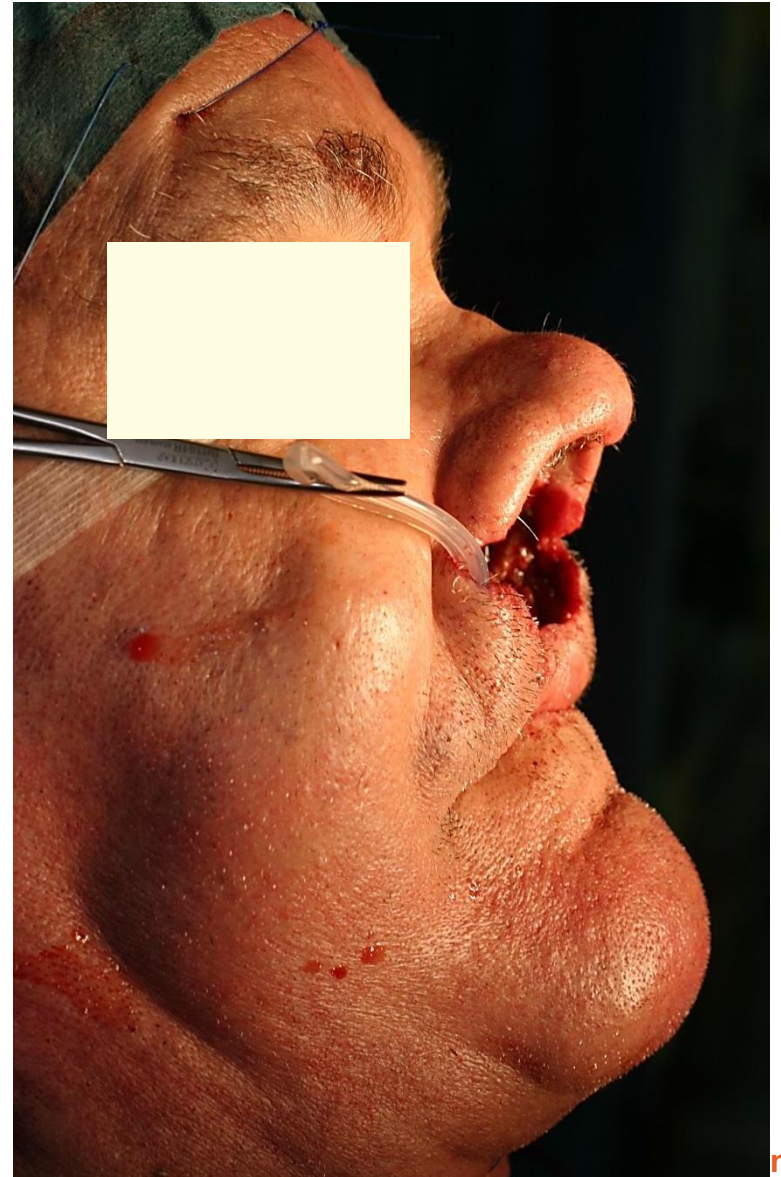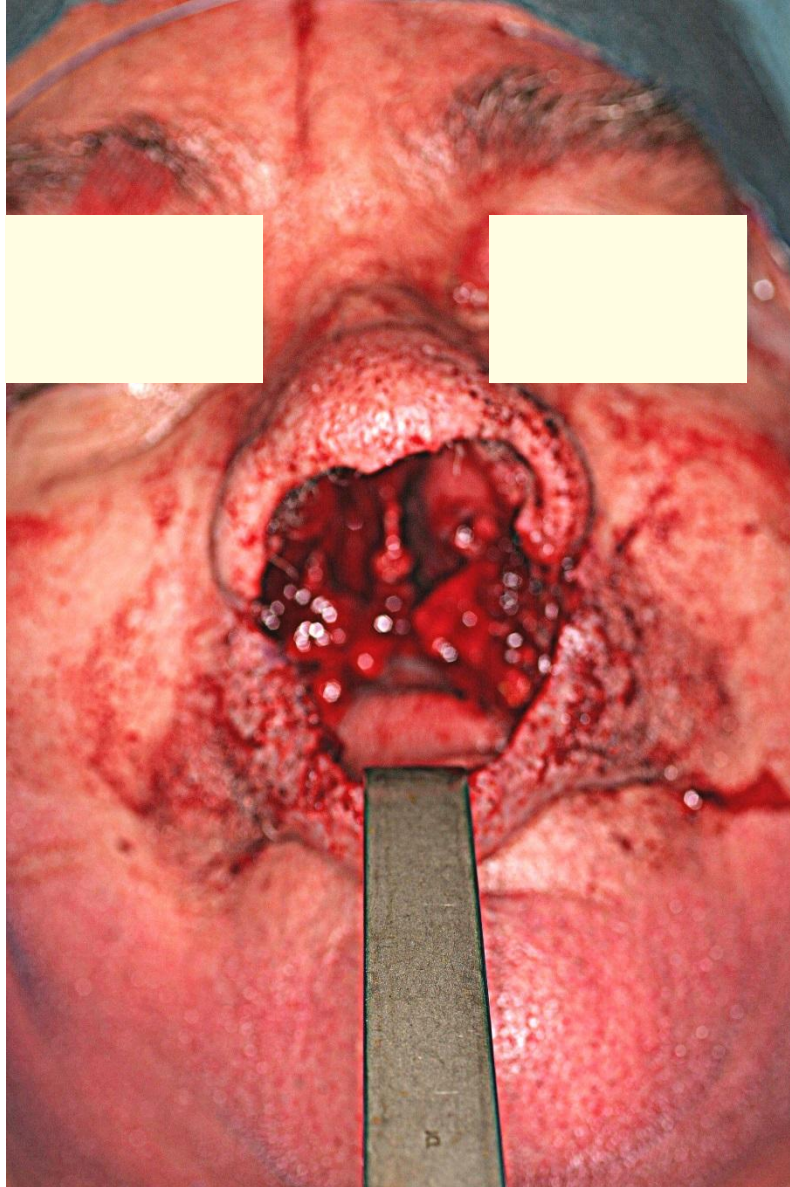


Amputation nasale avec maxillectomie antérieure

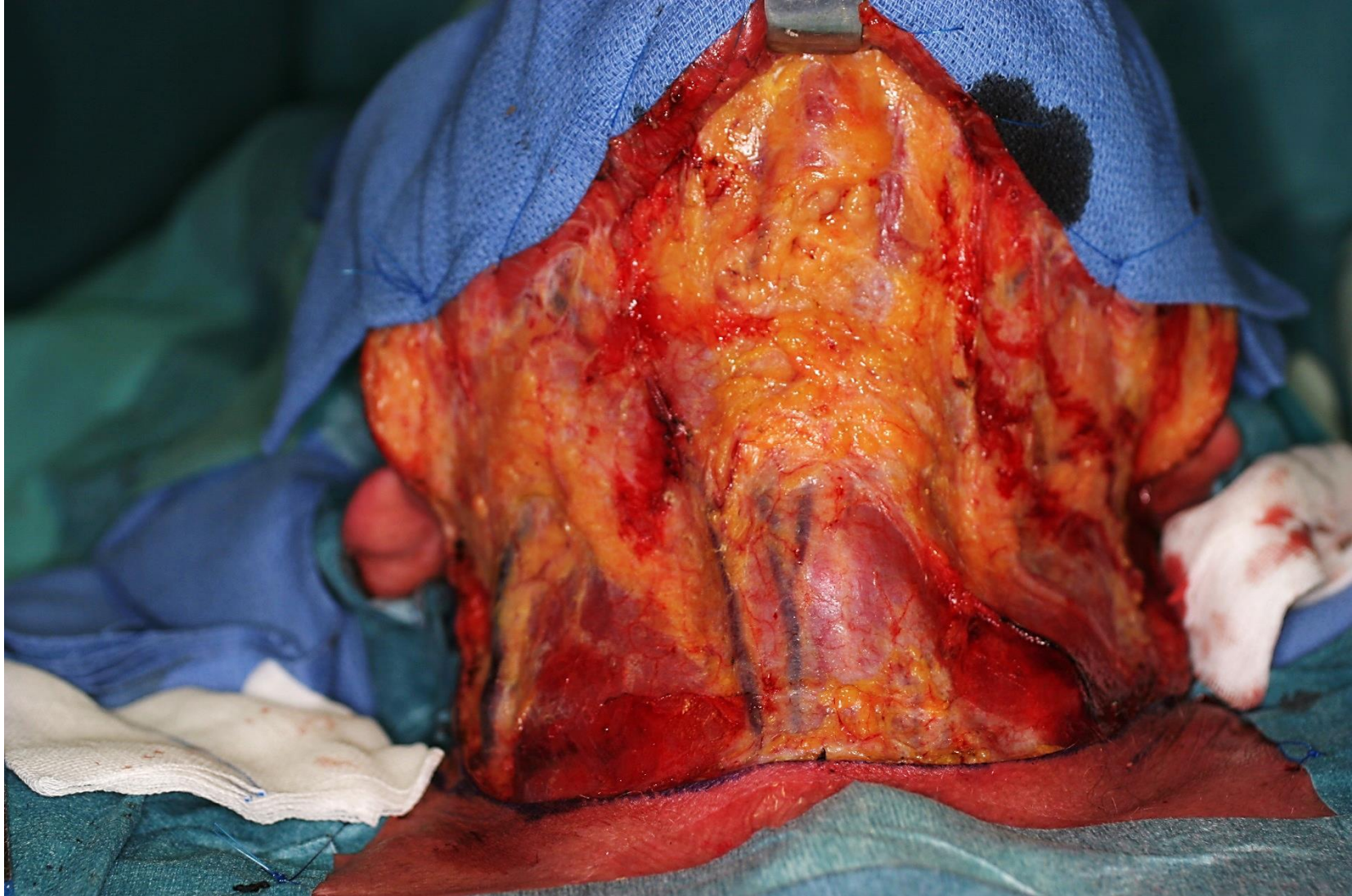



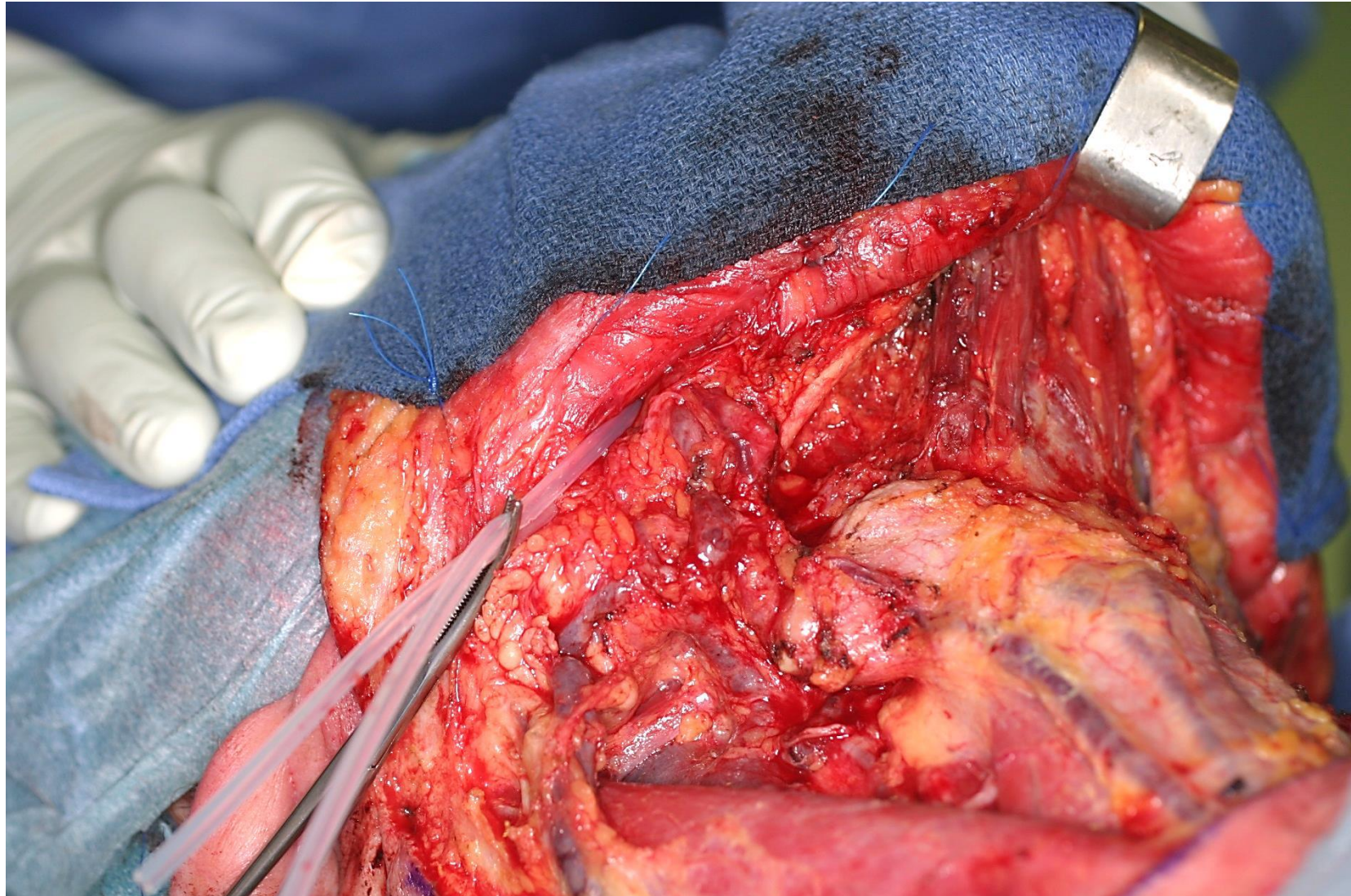
Recoupe berges examen extemporané

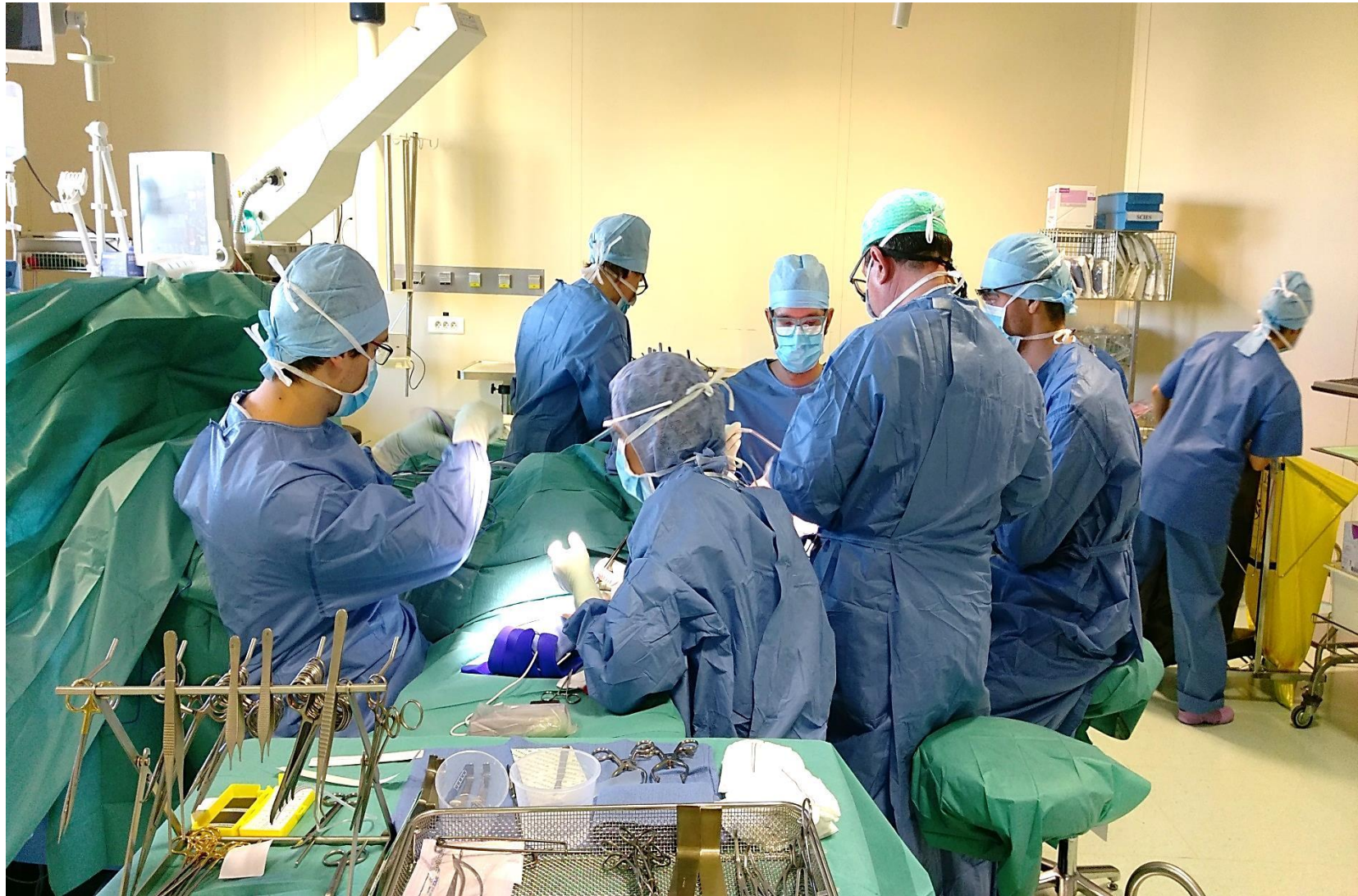

Curage cervical bilatéral



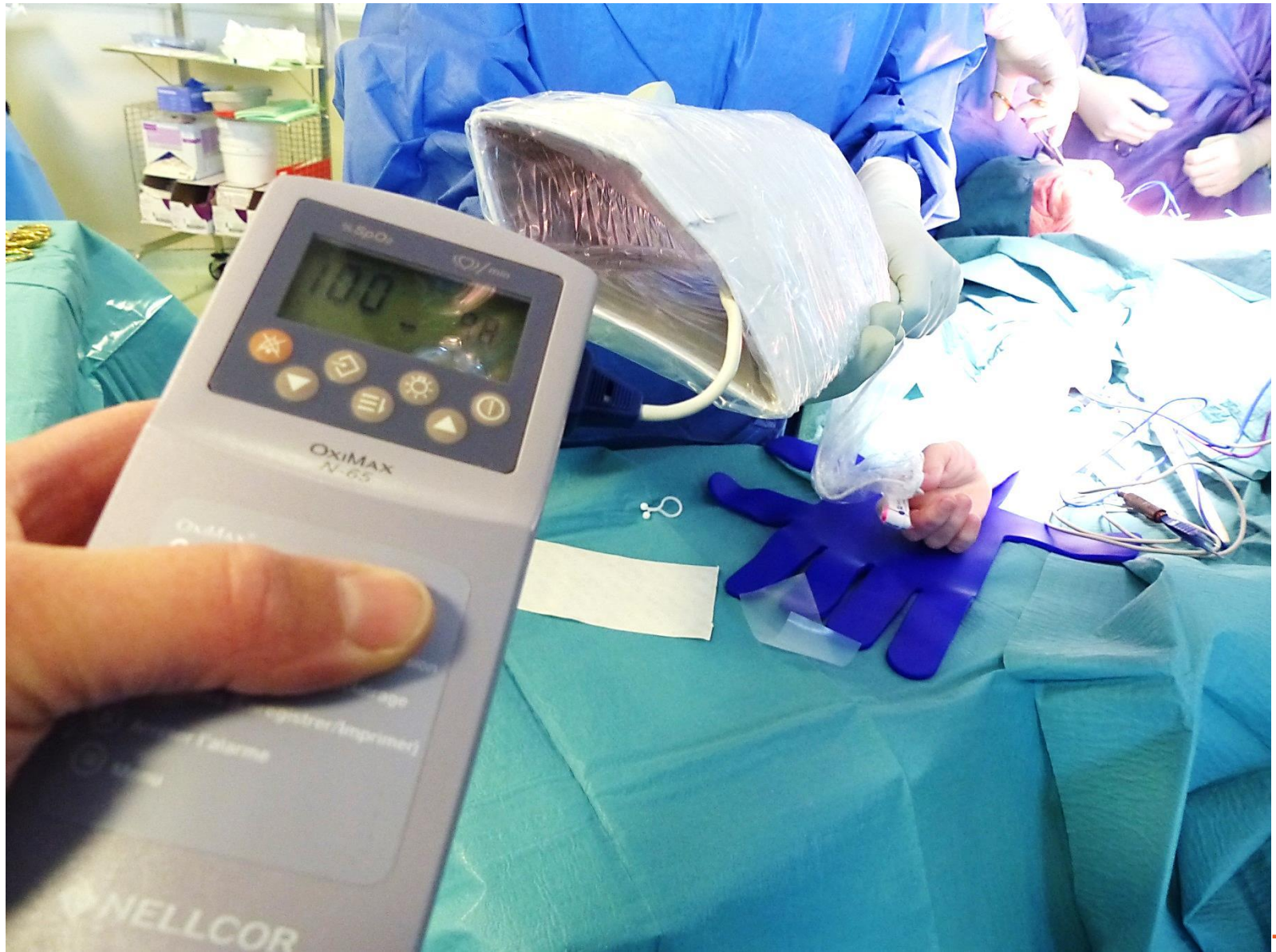Repérage pédicule et Tunnel





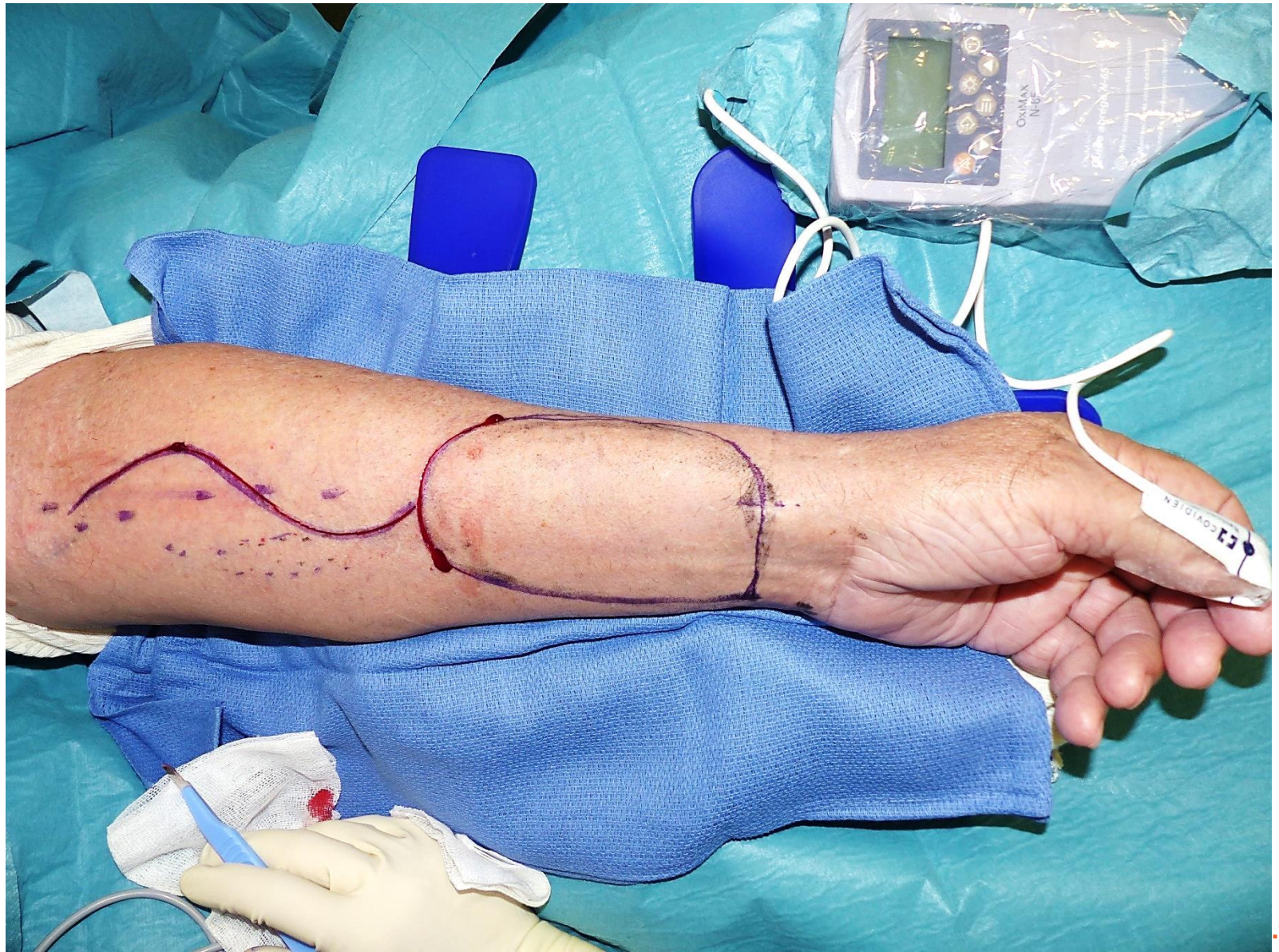

Saturomètre



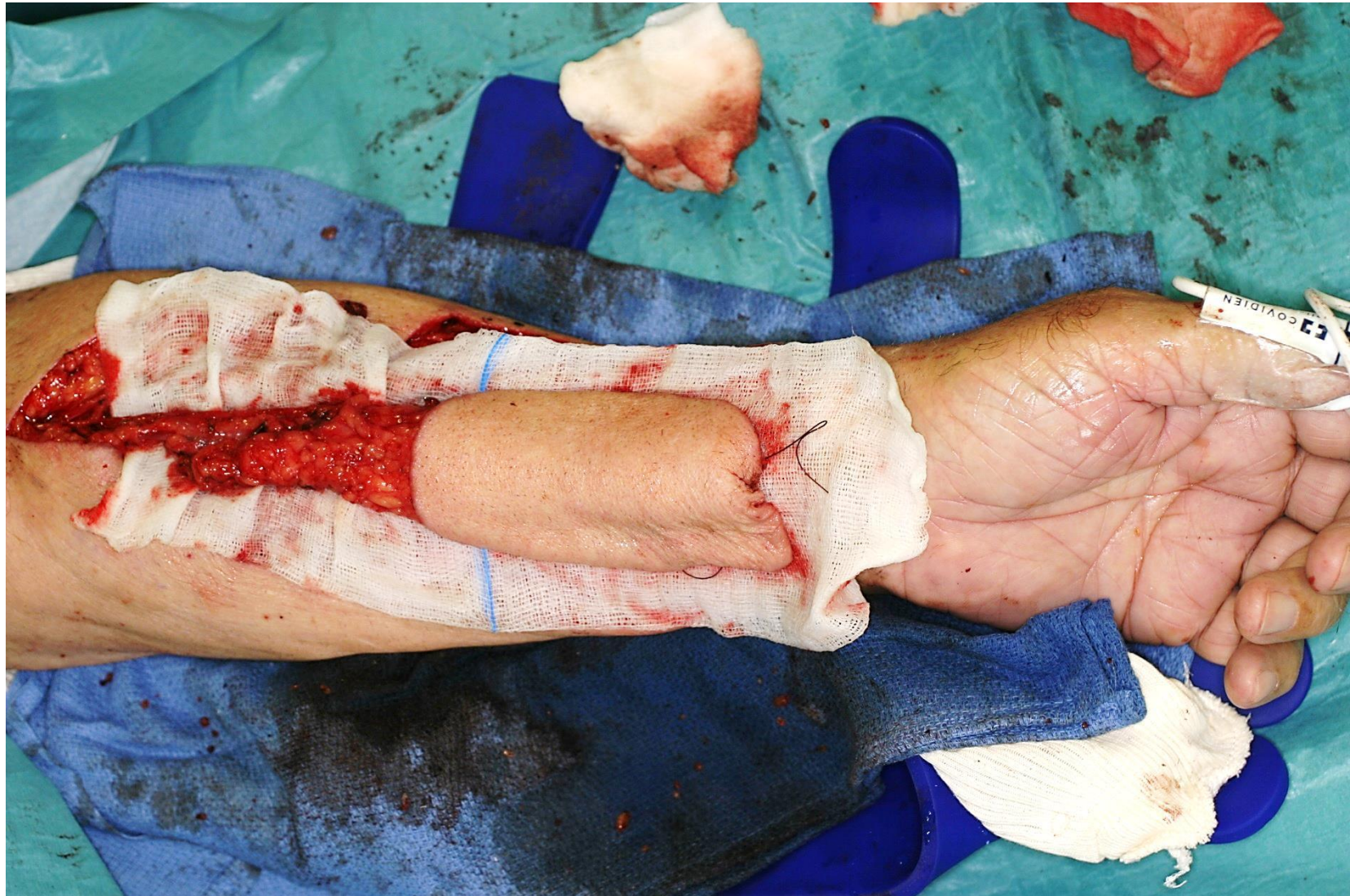

Evaluation de la taille et incision





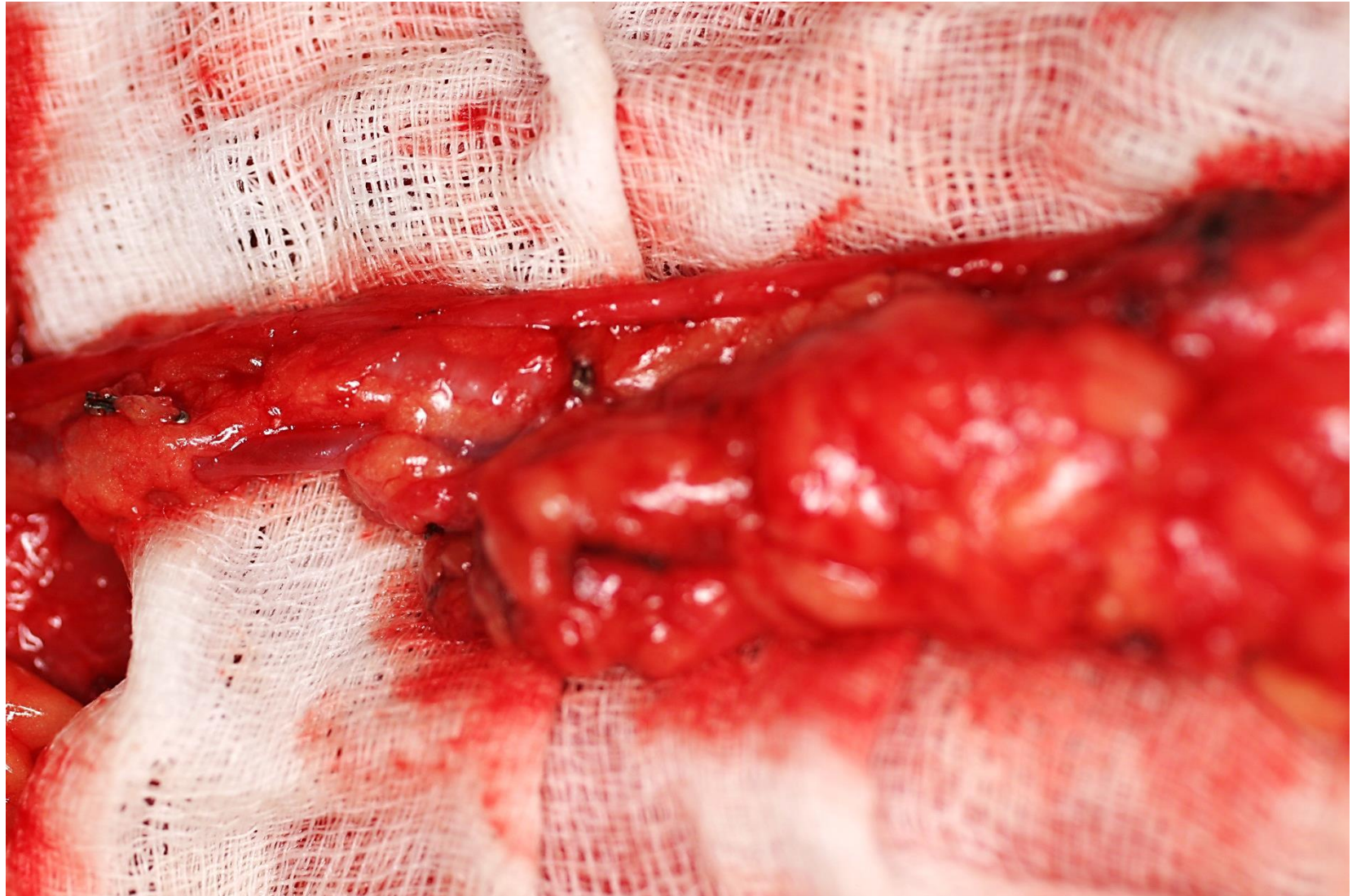
Dissection, section distale pédicule radial





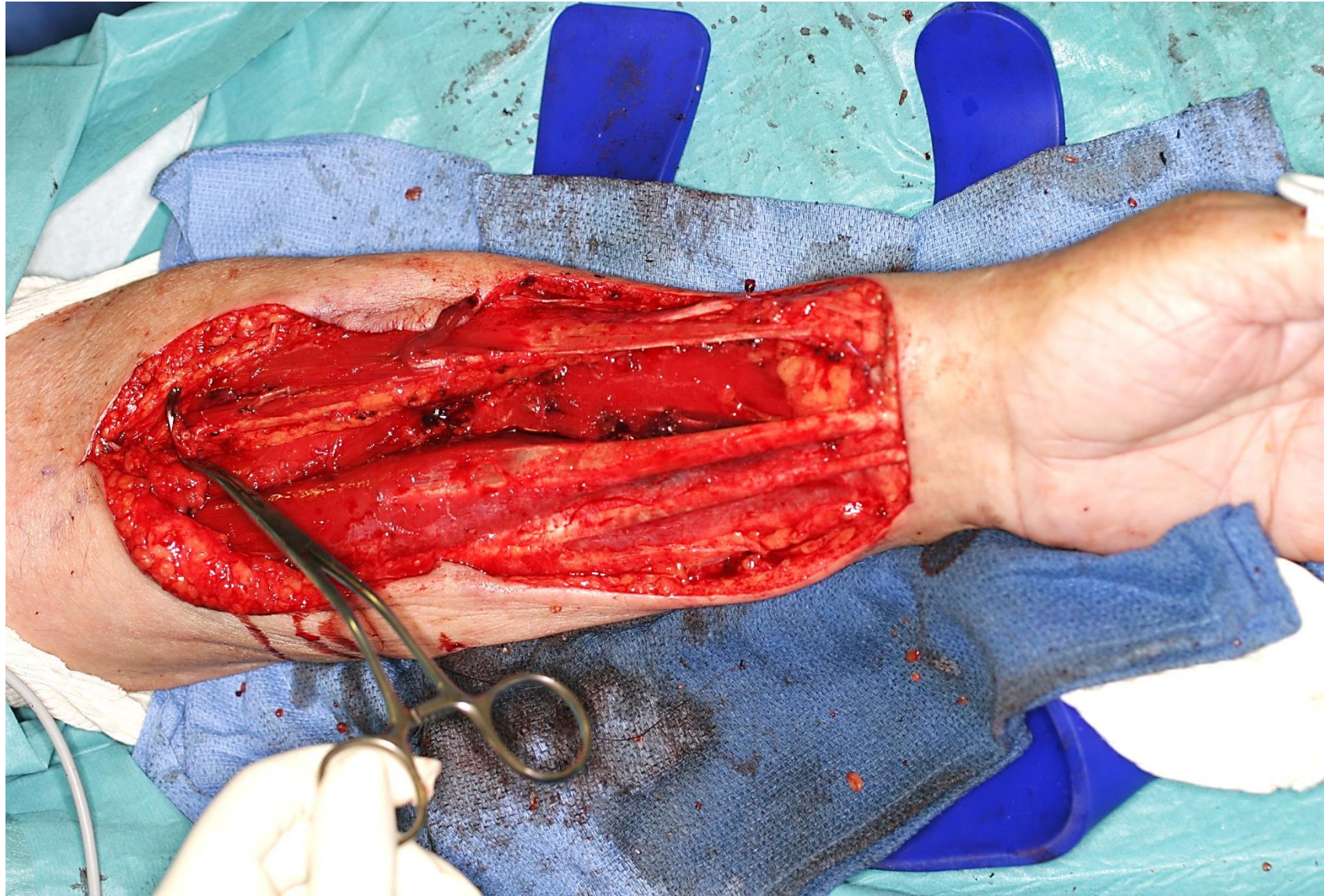Pédicule radial en proximal

1 artère et 2 veines + 1 veine accessoire

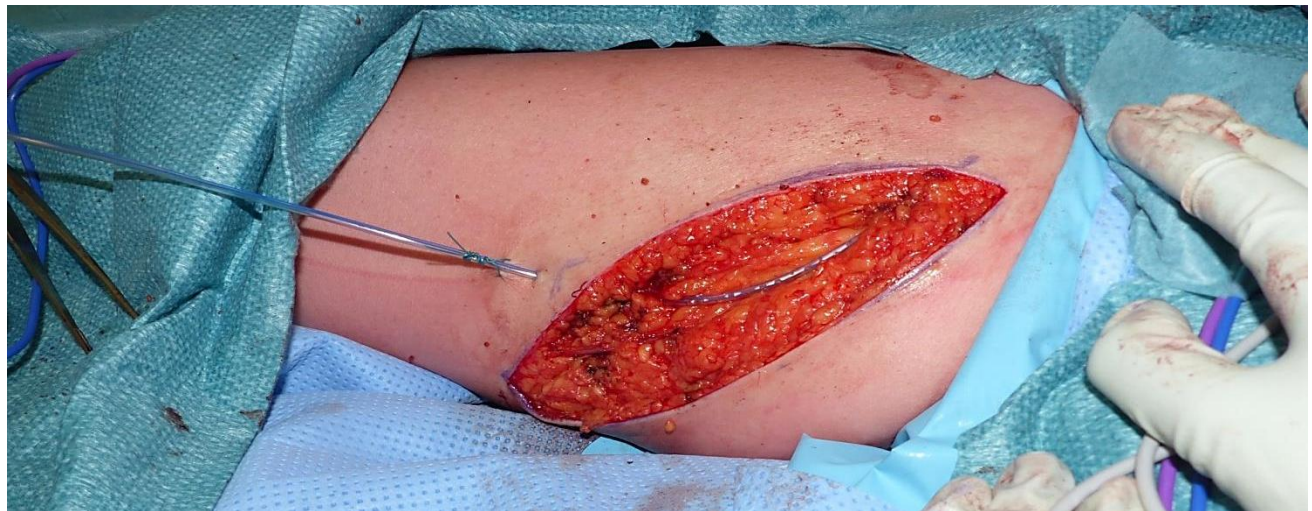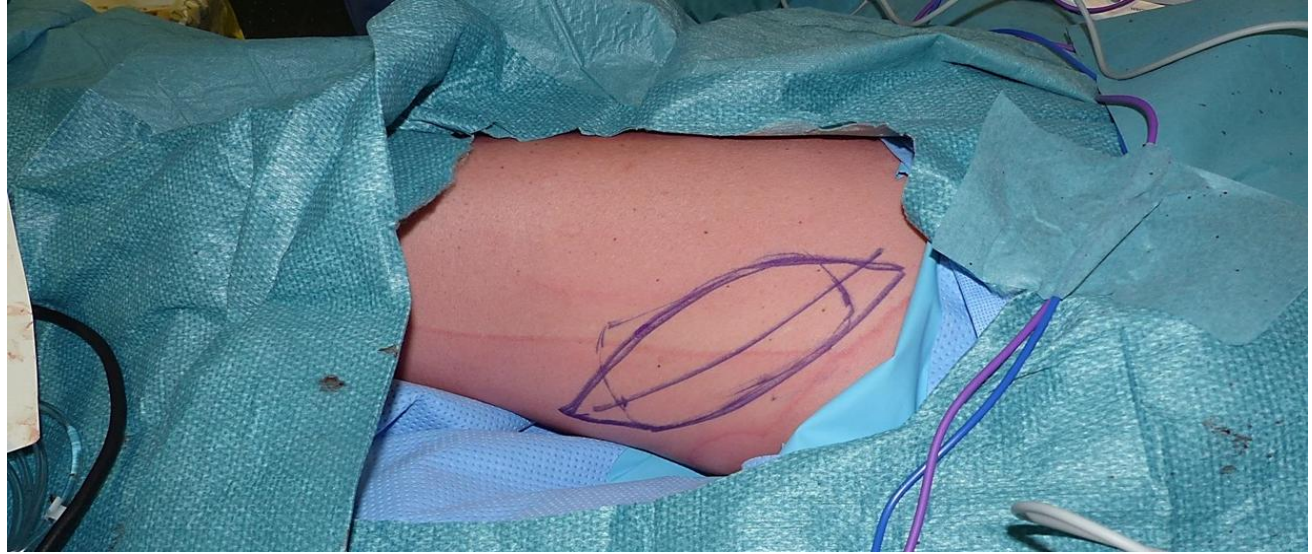




Héparinisation I.V. et section

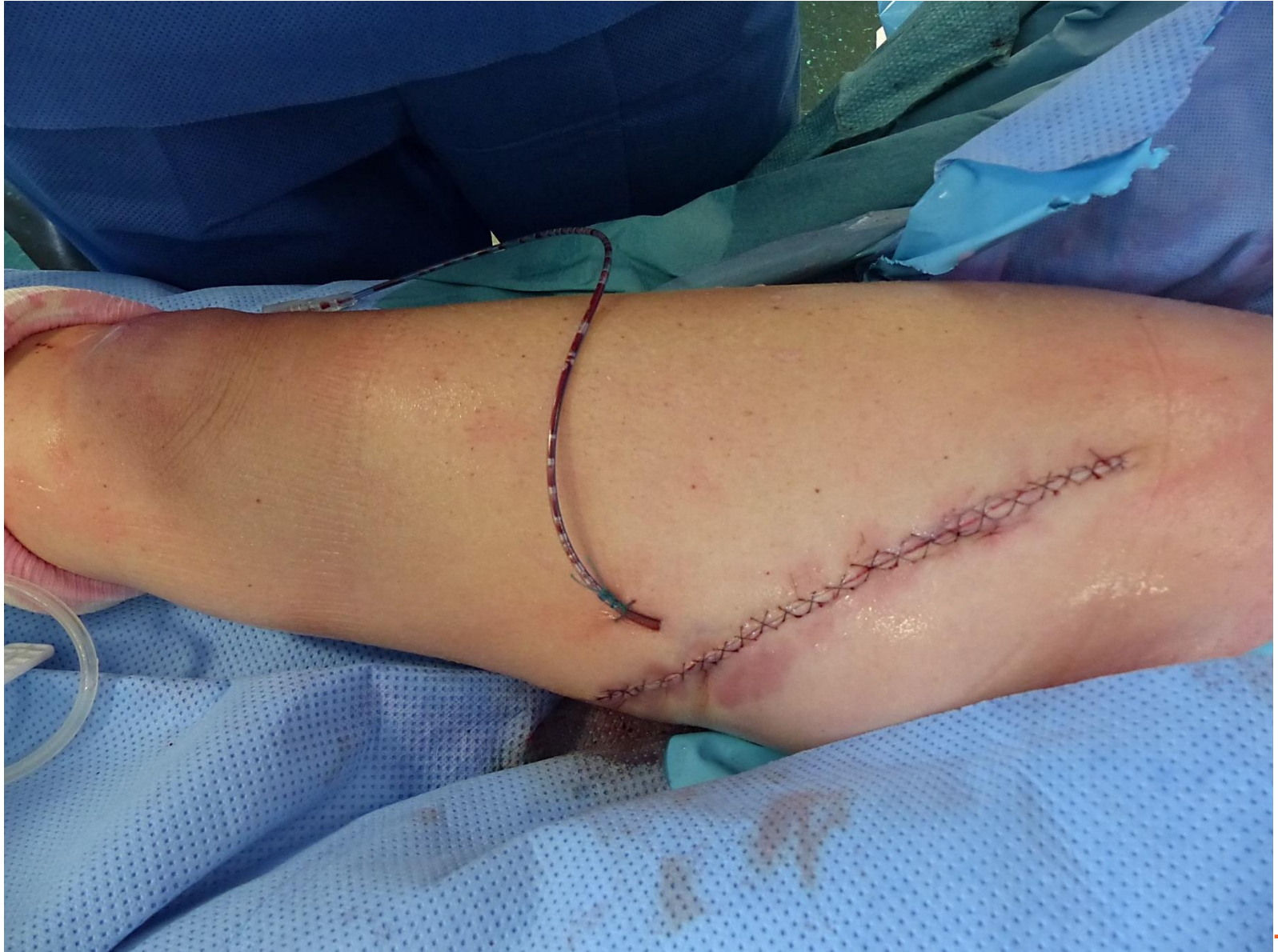

Face interne cuisse

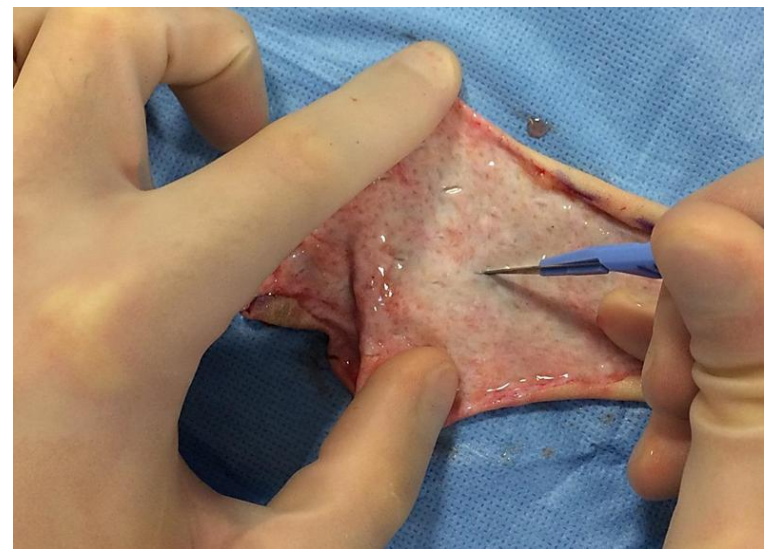
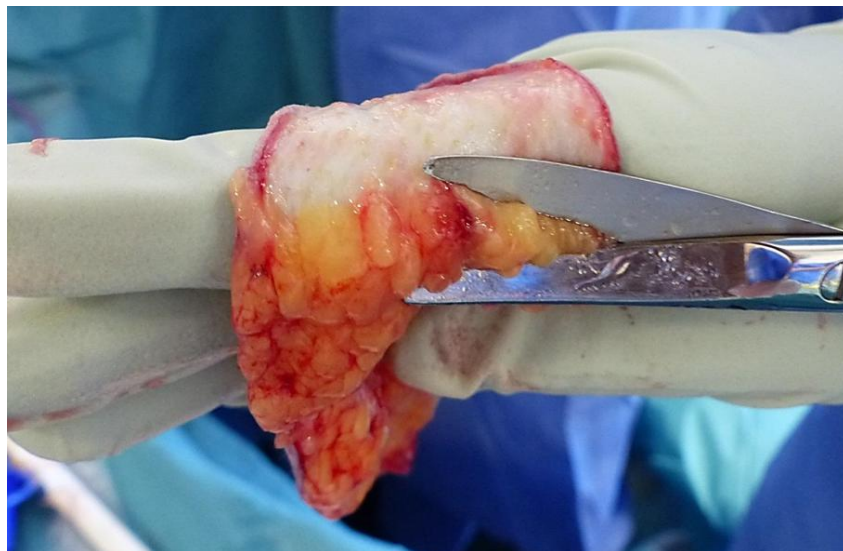
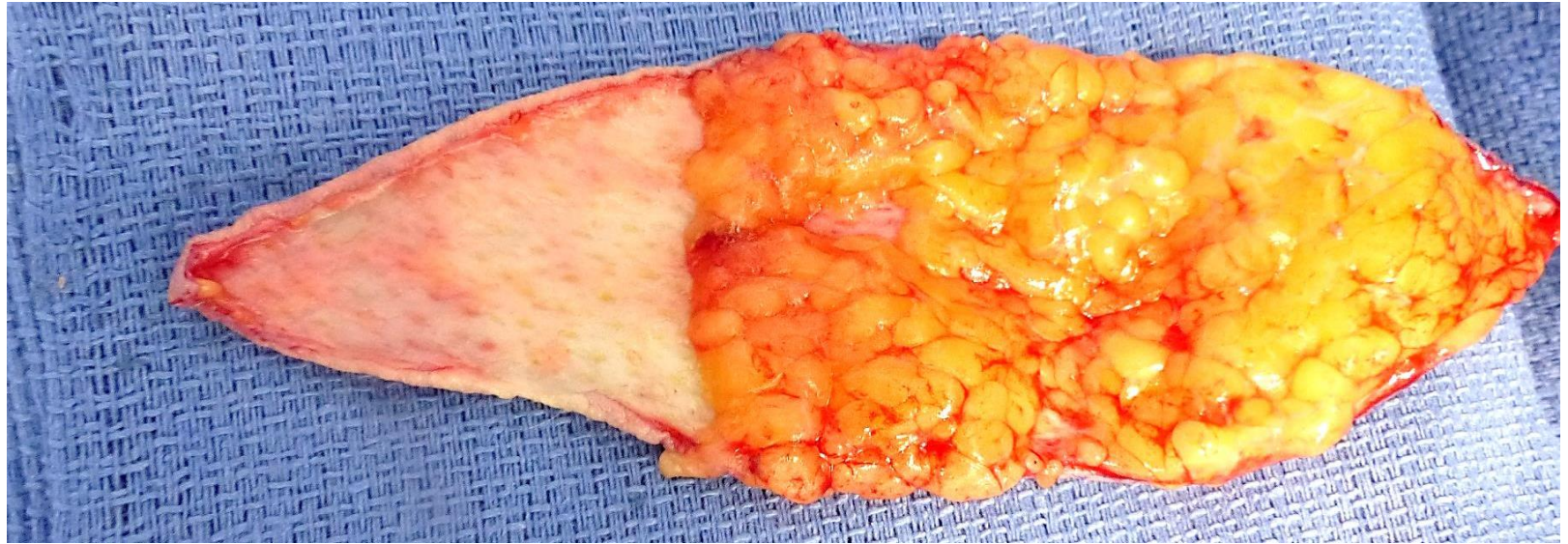




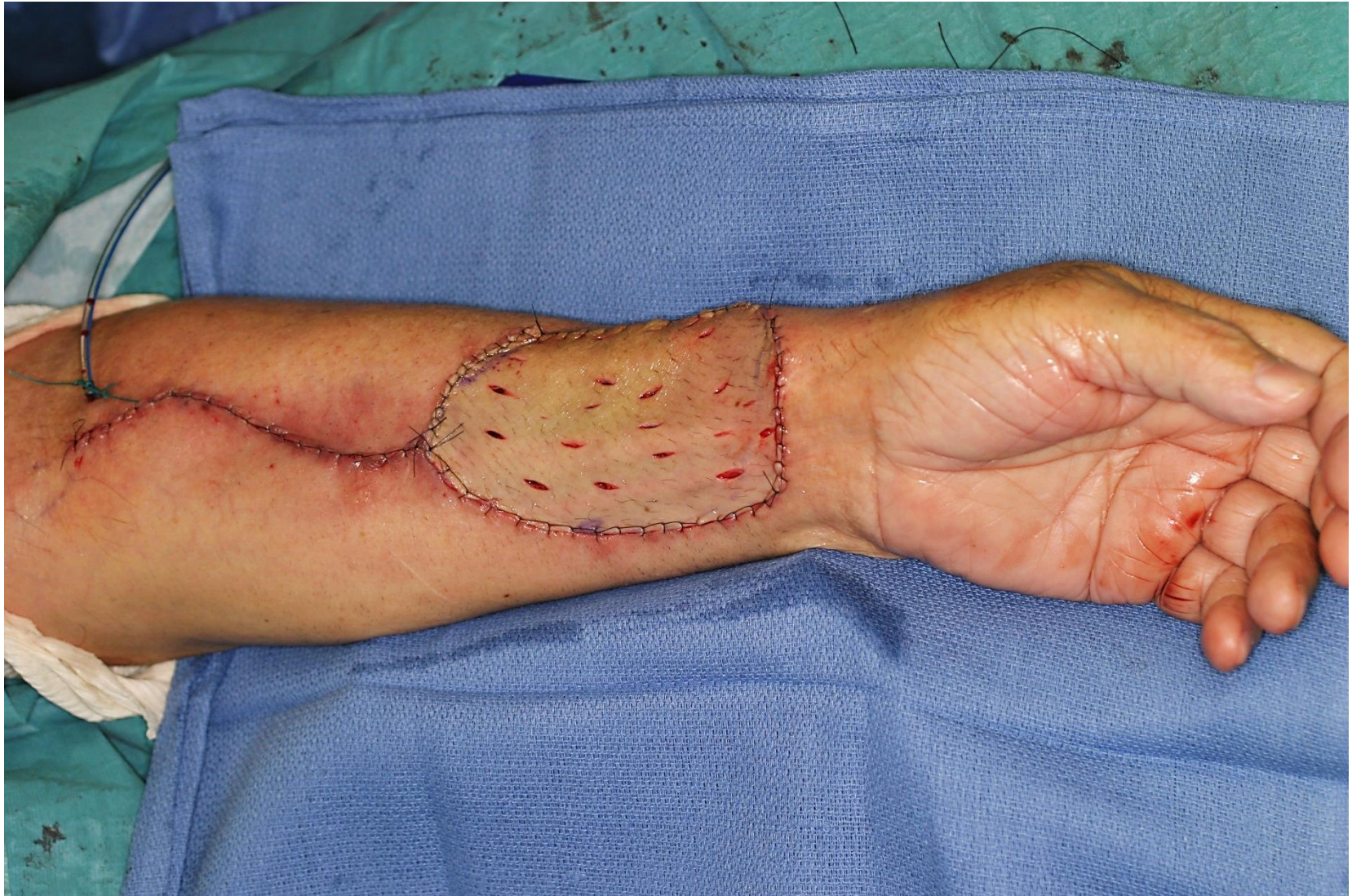Drainage et fermeture

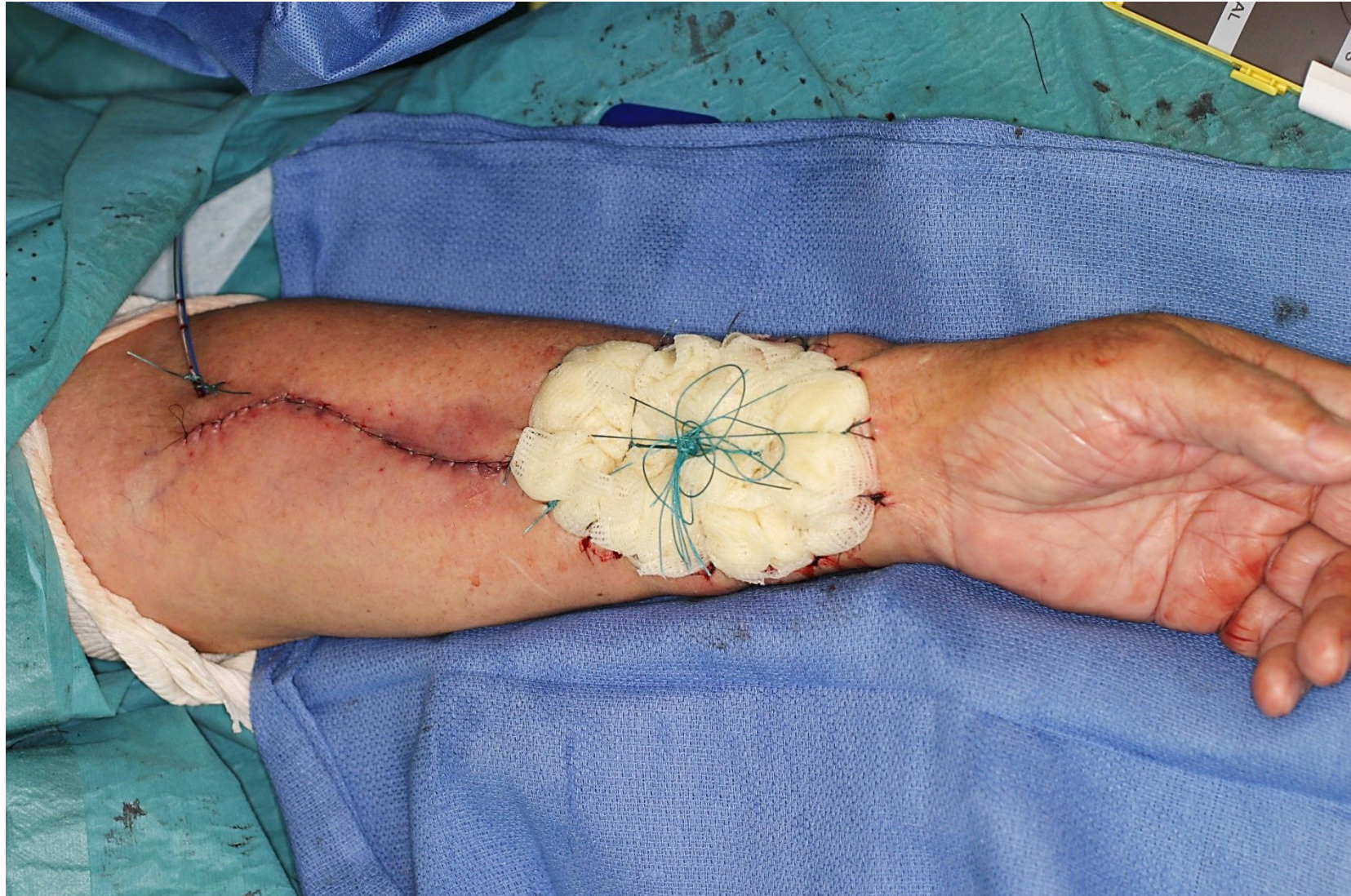

Préparation de la greffe



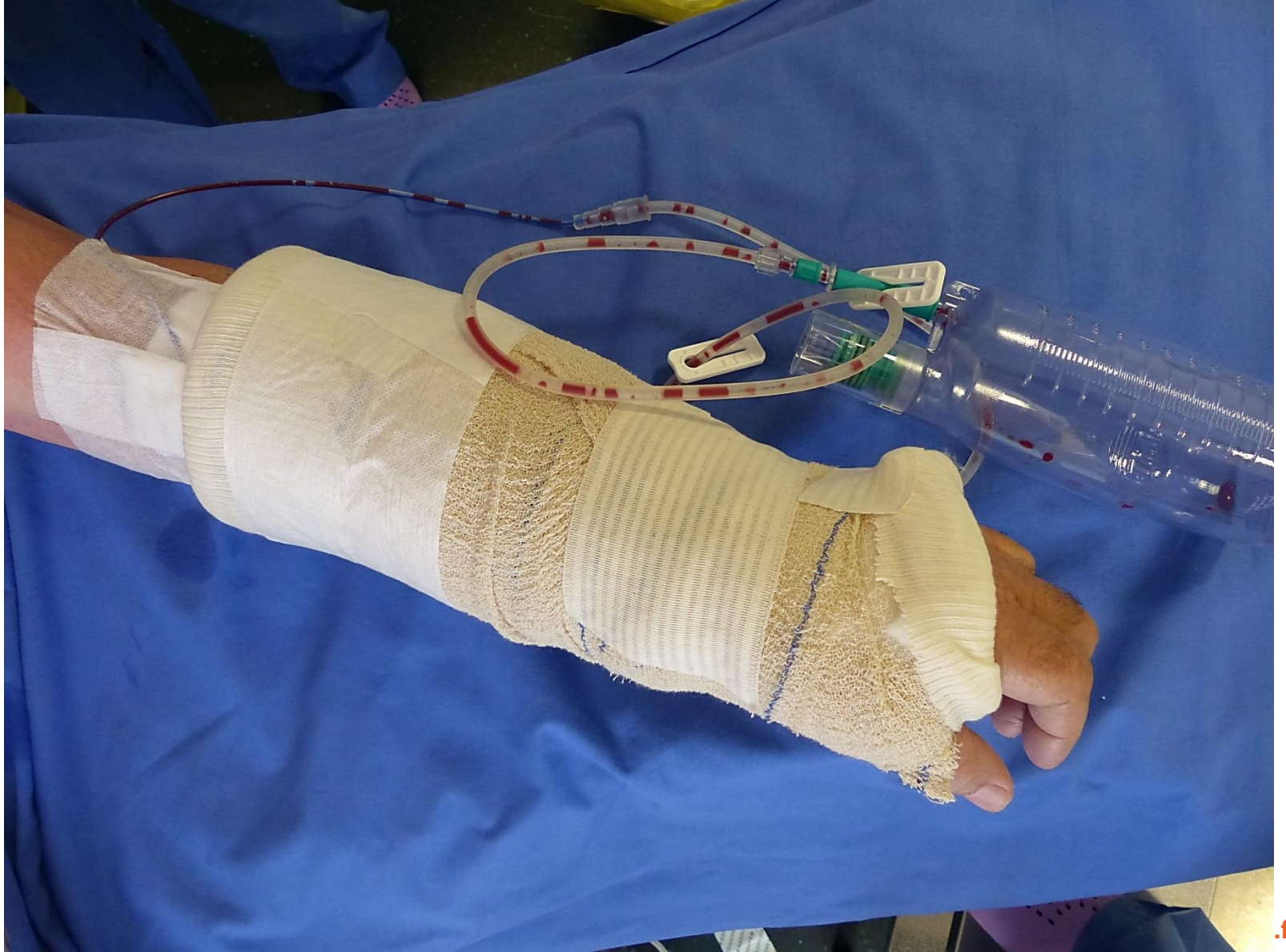Sutures





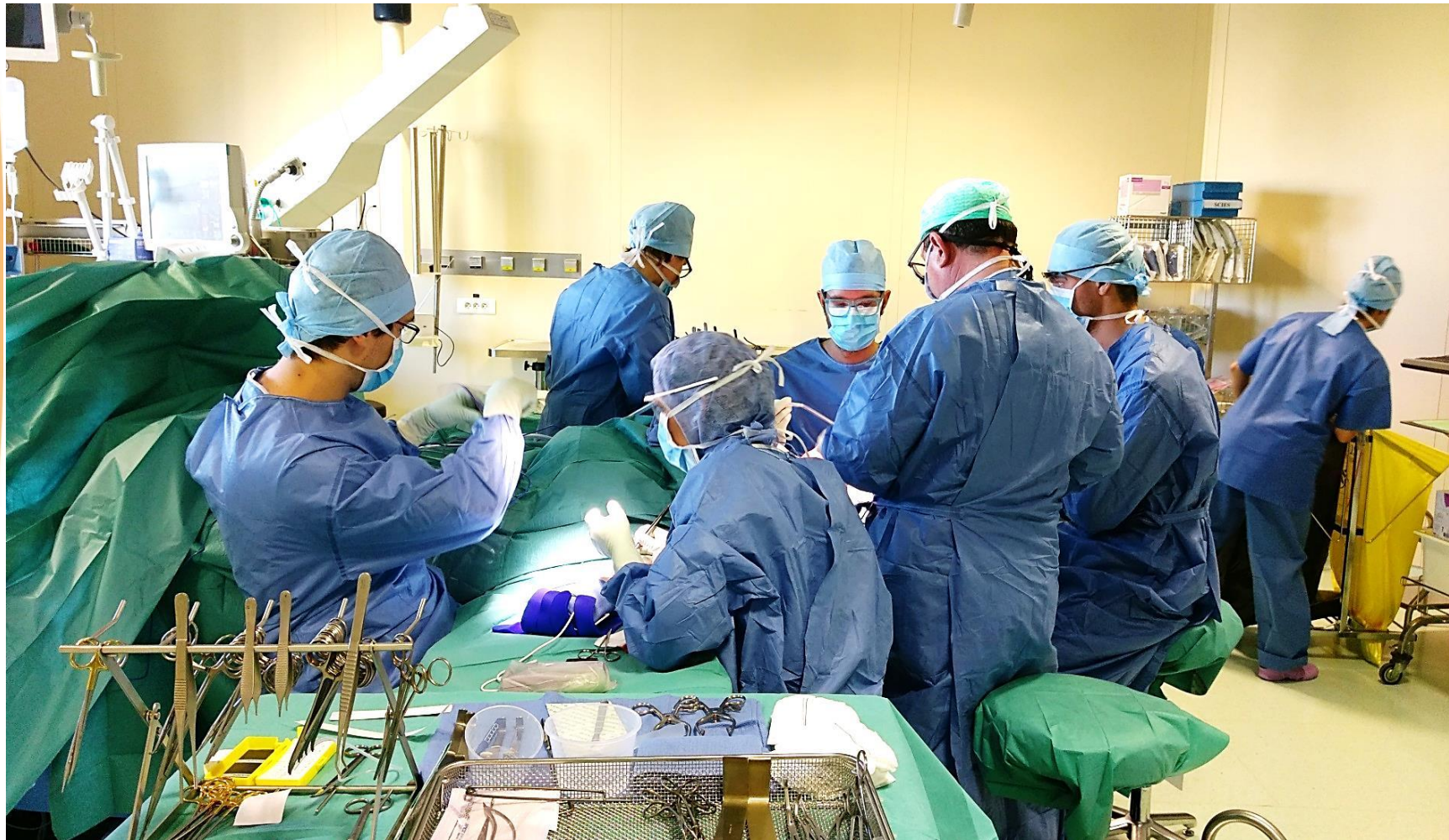

Attelle plâtrée



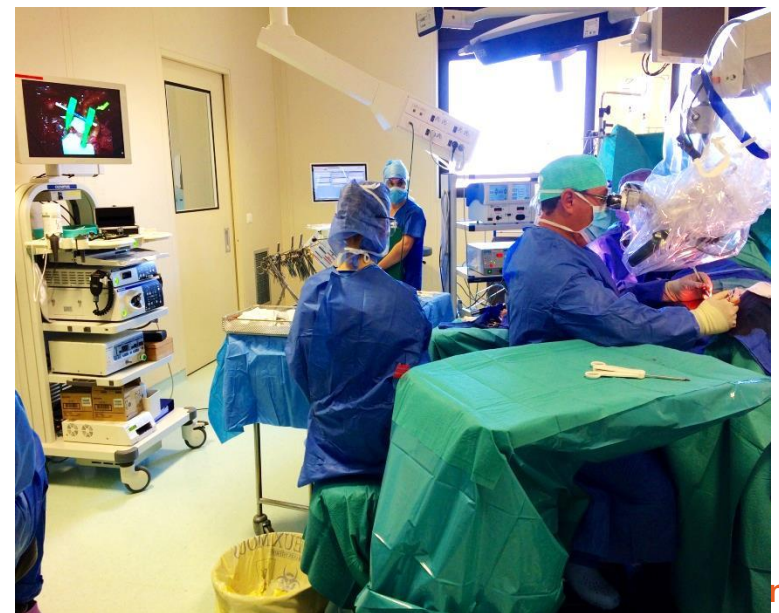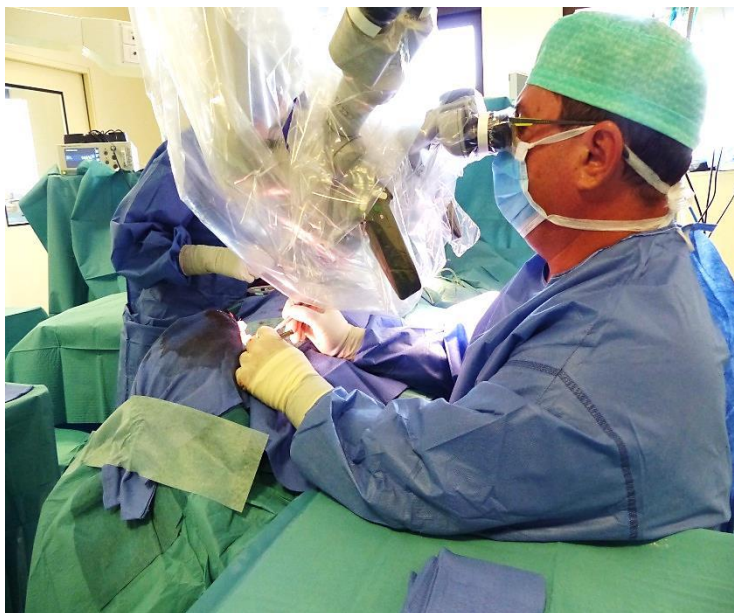

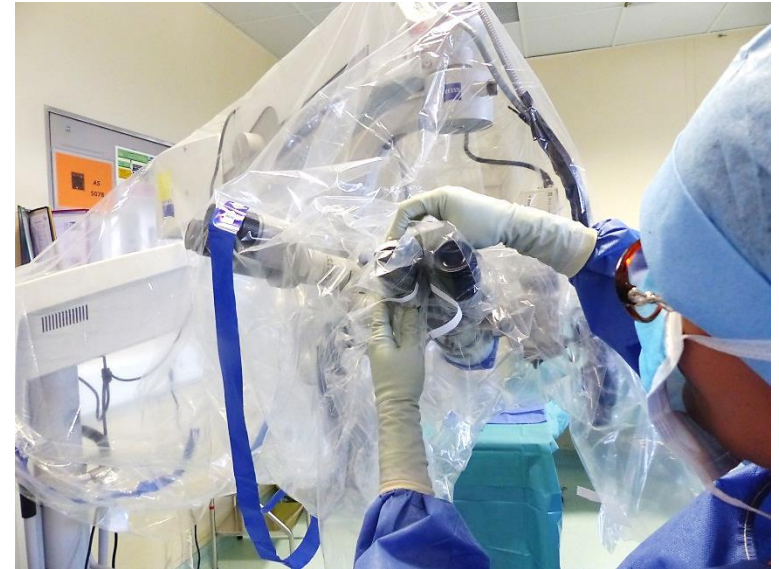
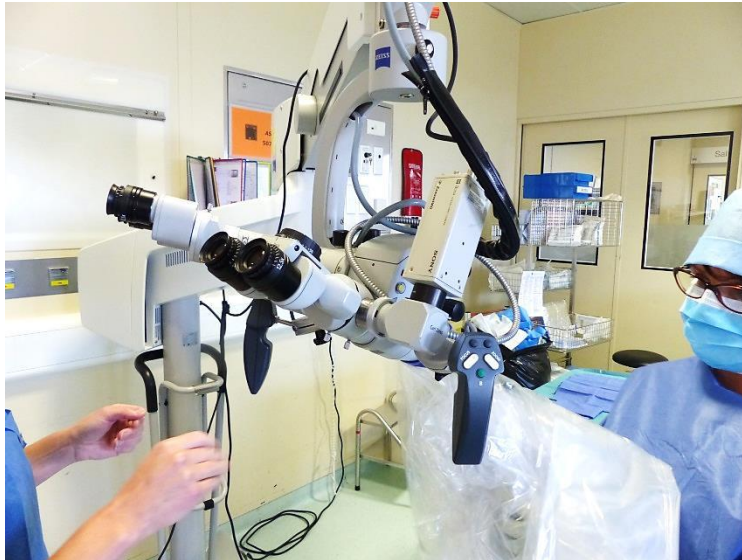Microchirurgie





Microscope

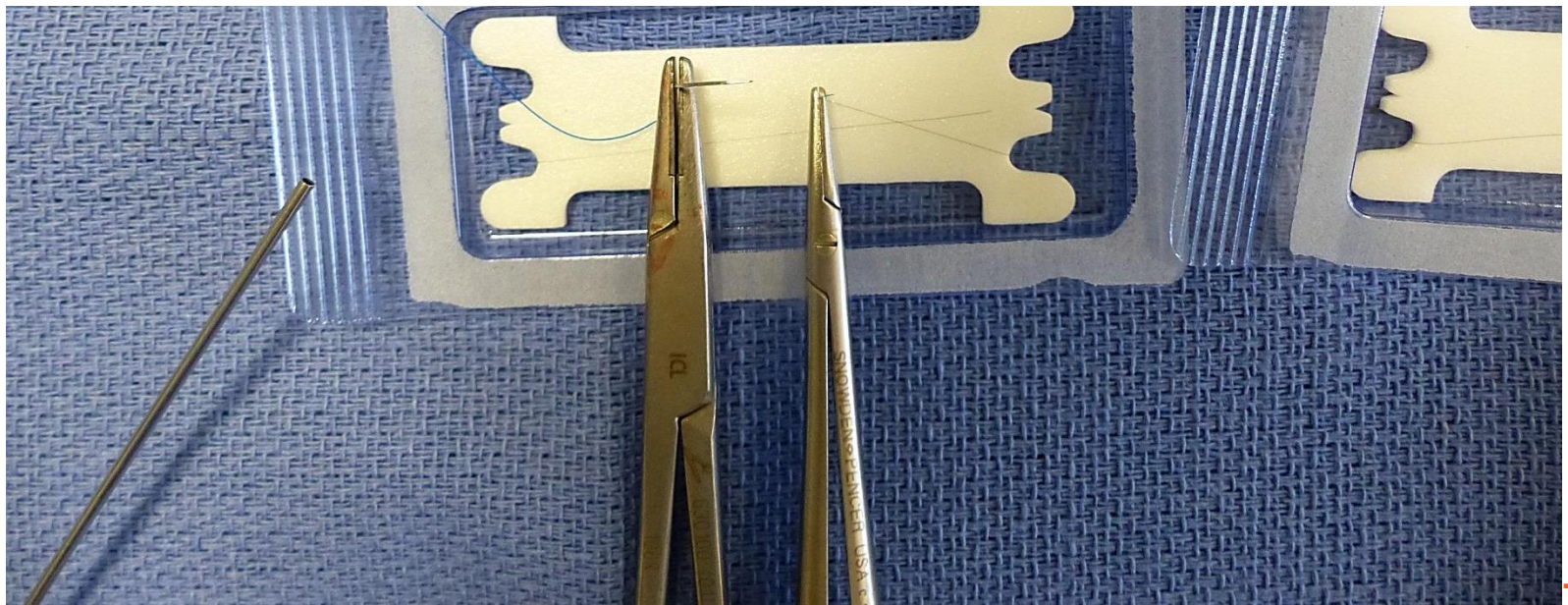
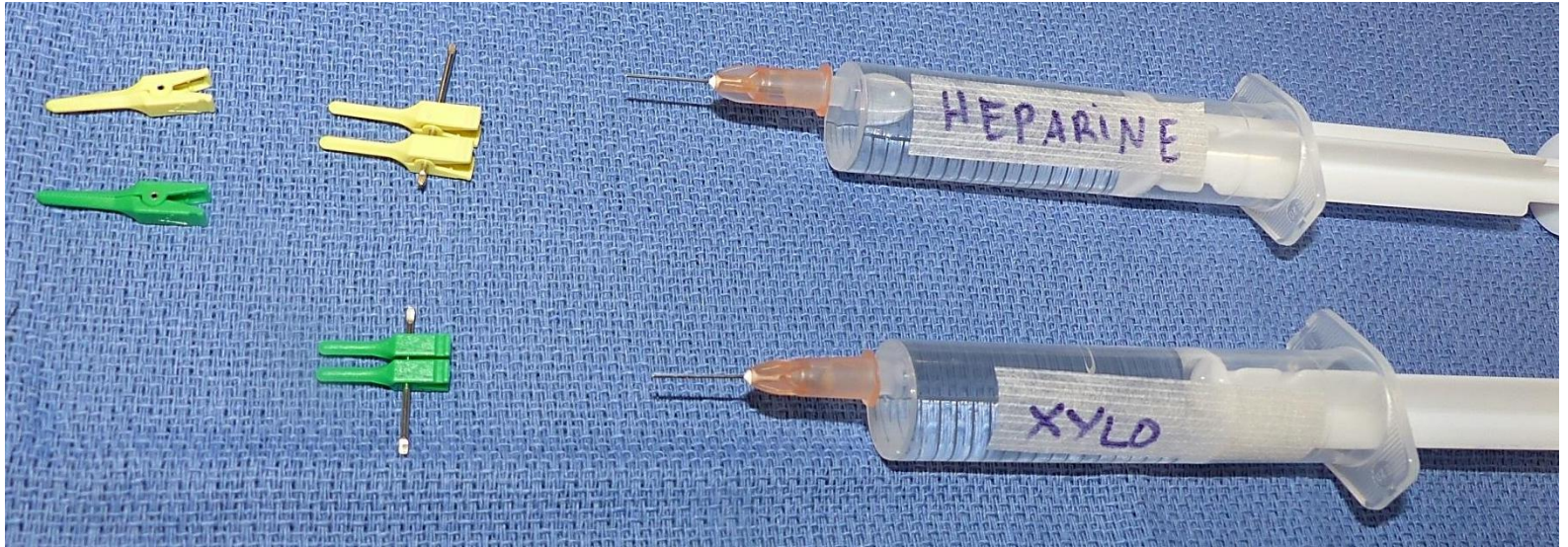



Instruments microchirurgie

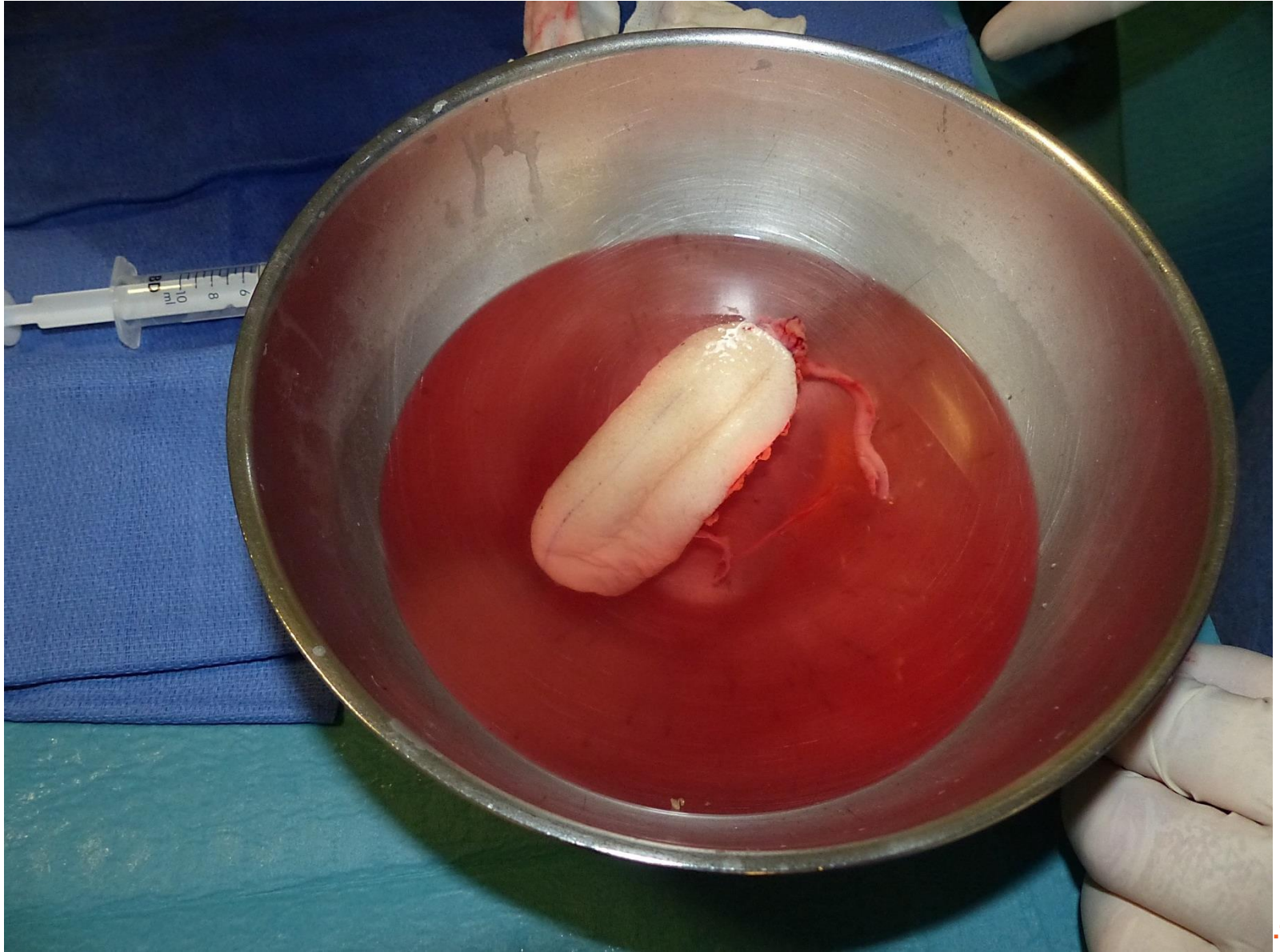

Microchirurgie



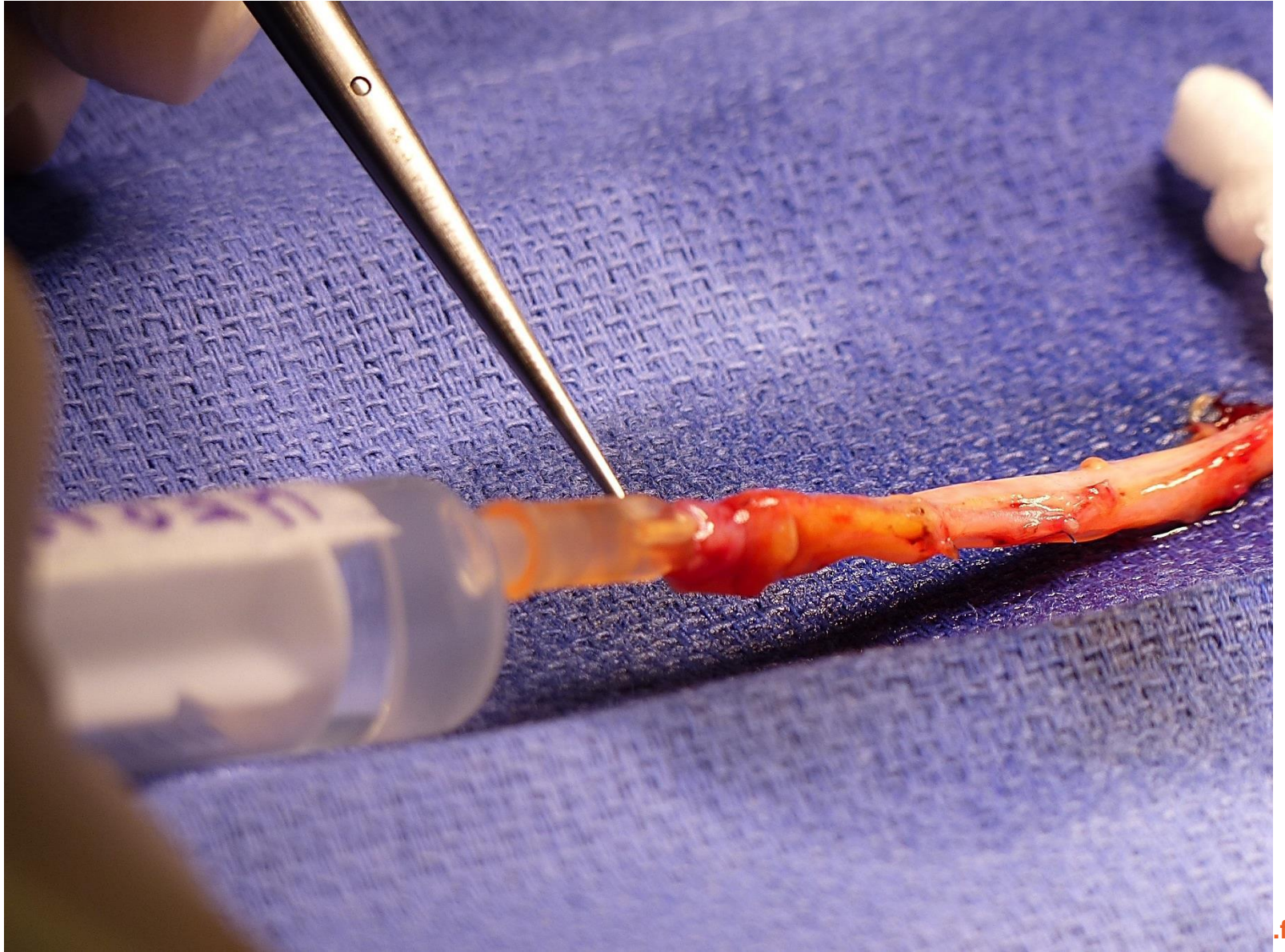


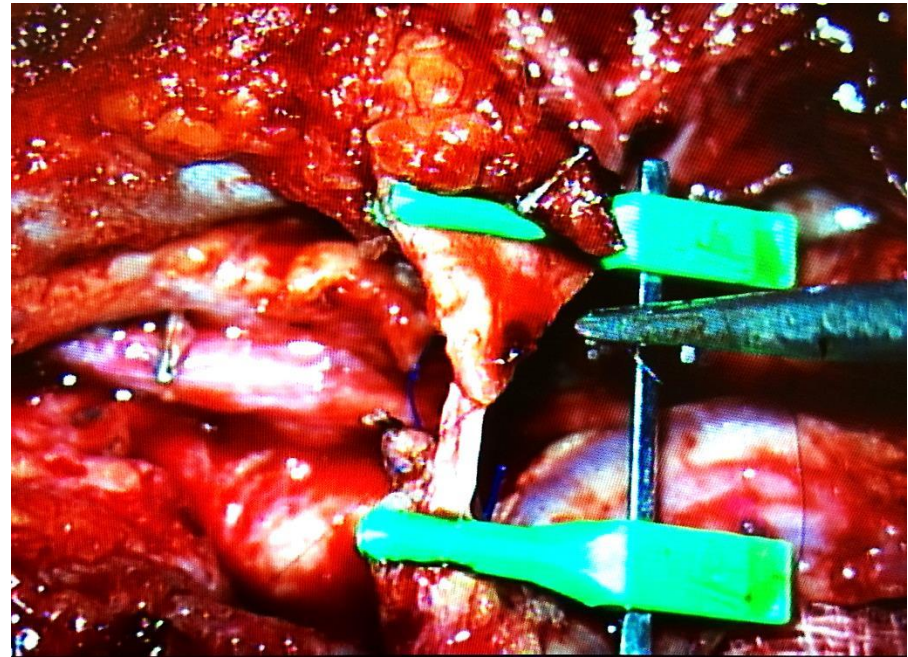
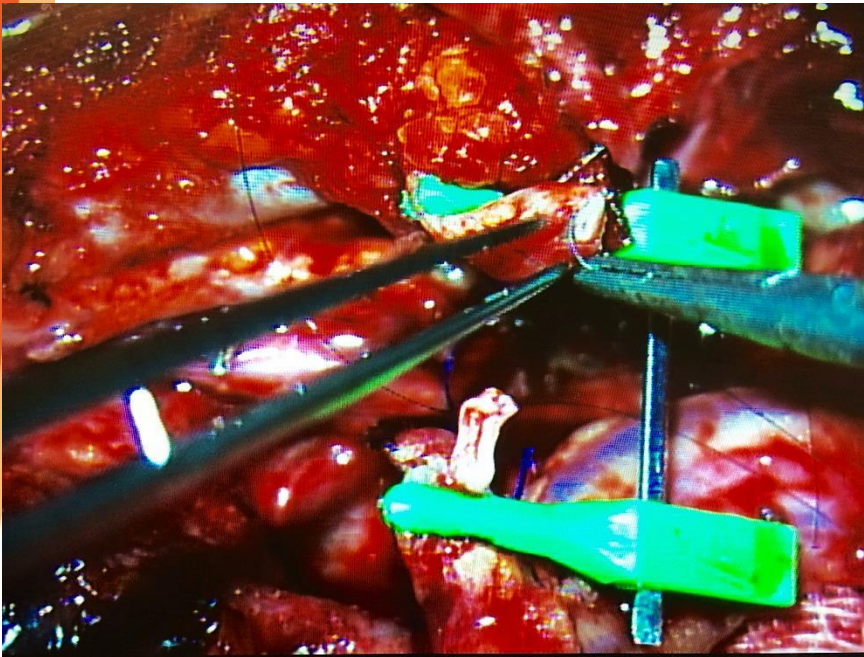
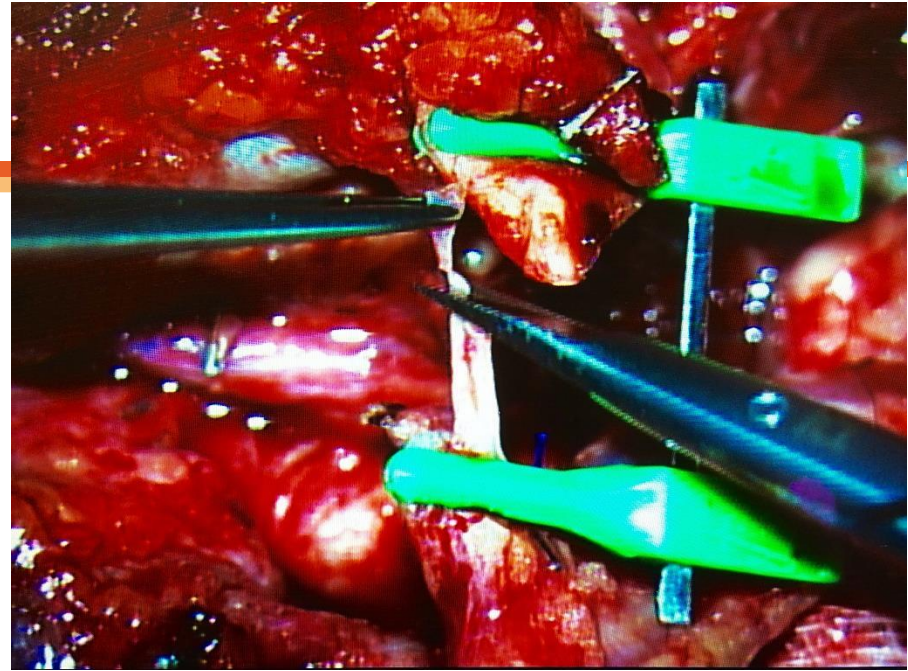
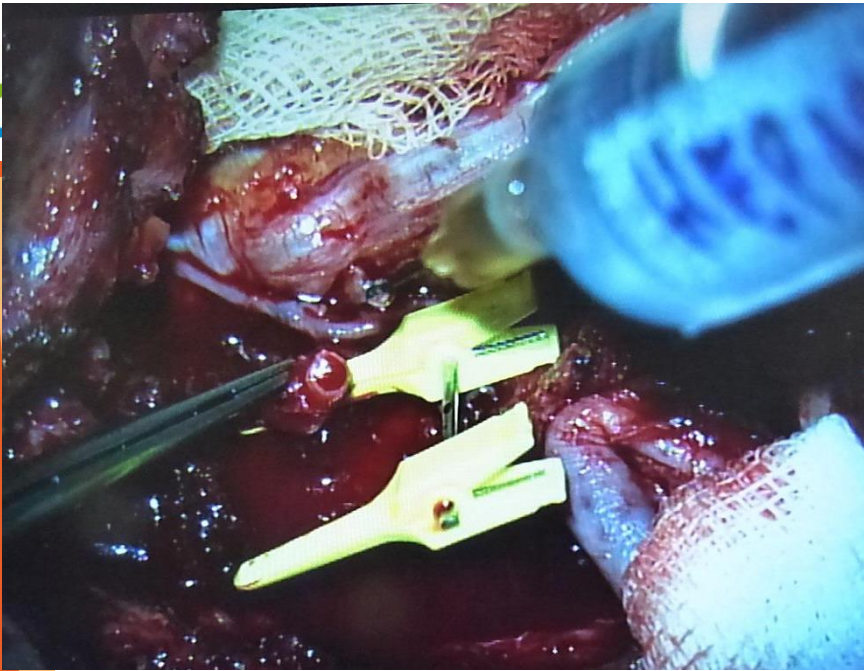
Lambeau





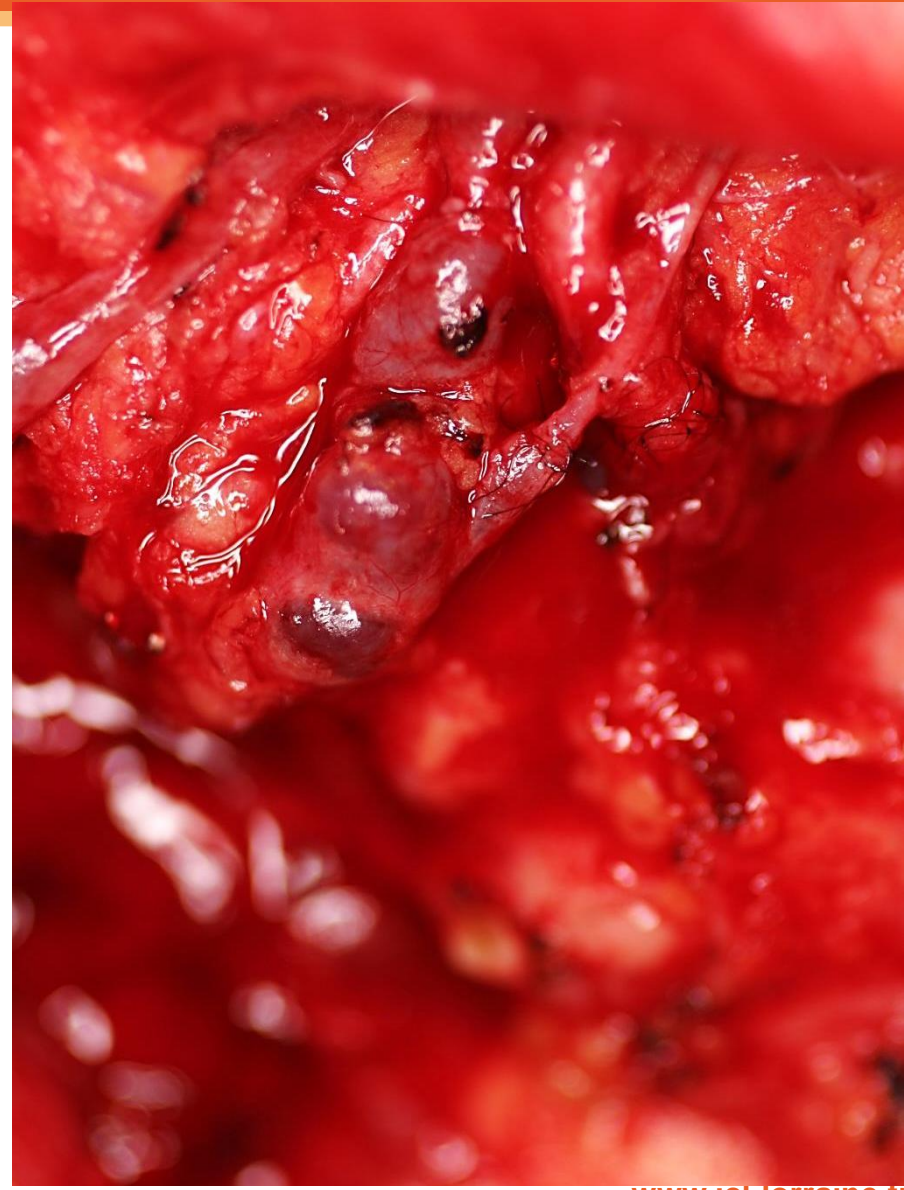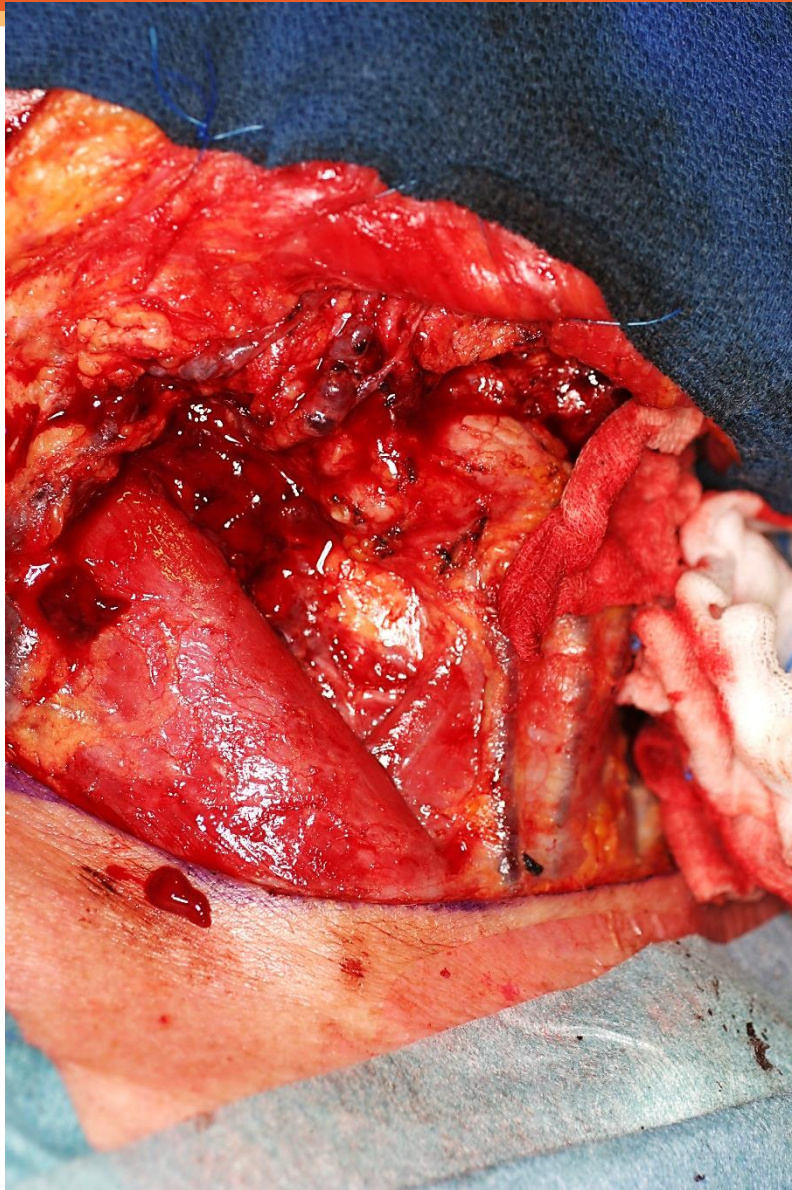
Rinçage pédicule du lambeau



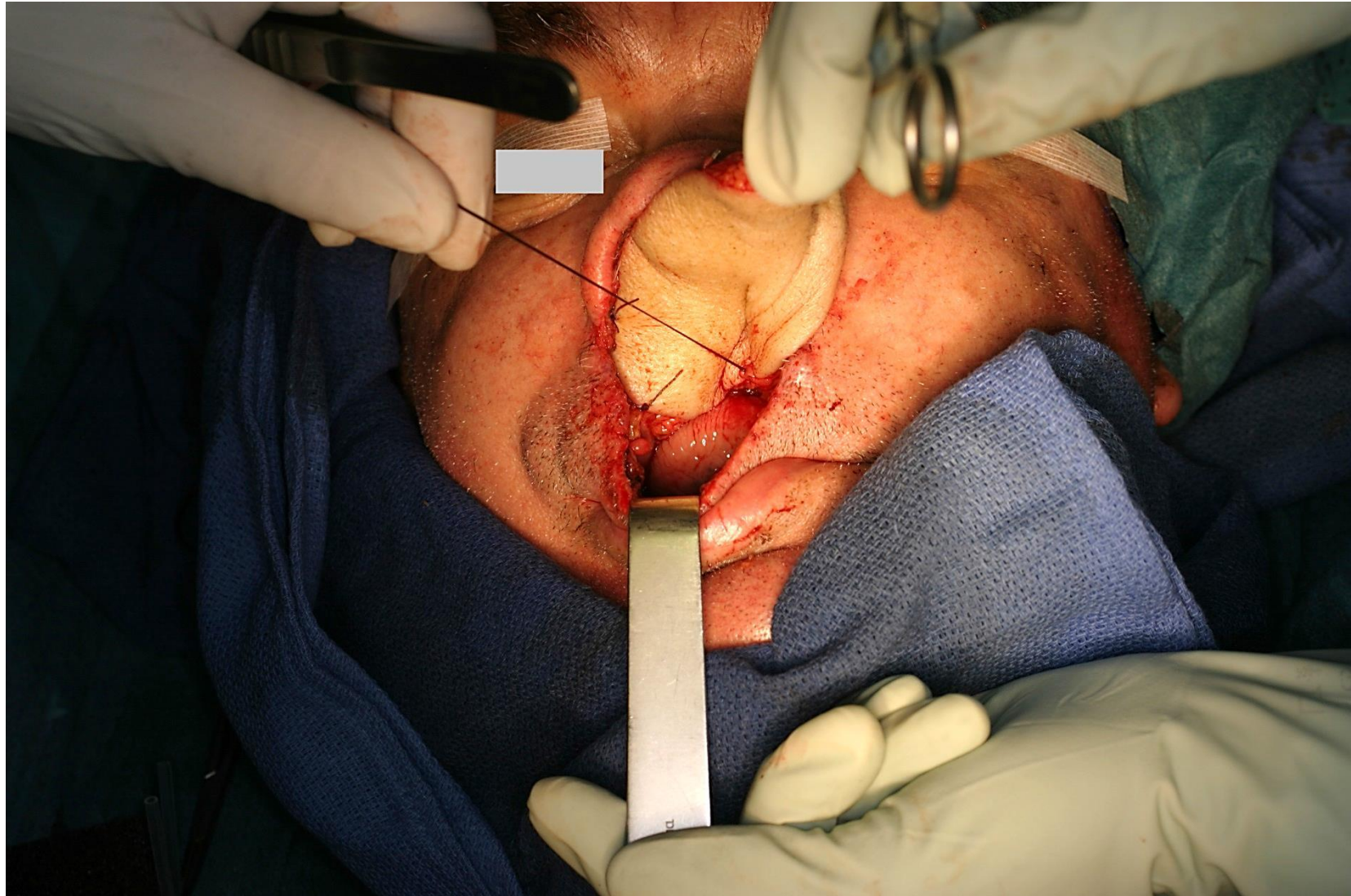




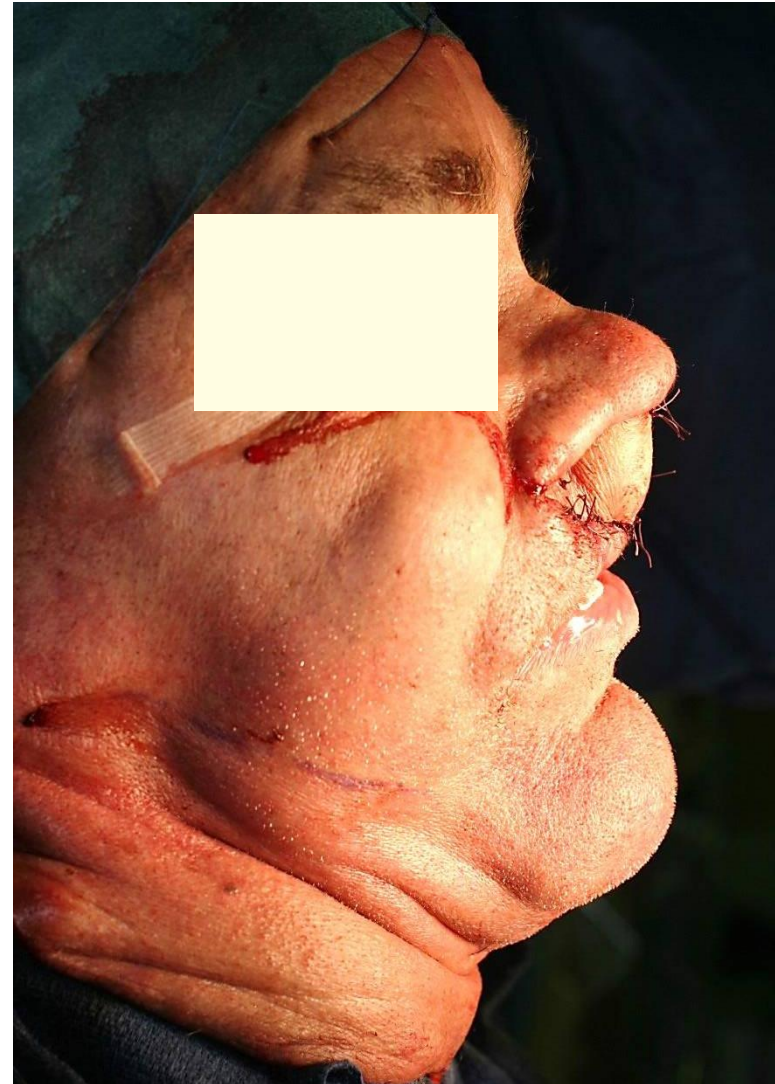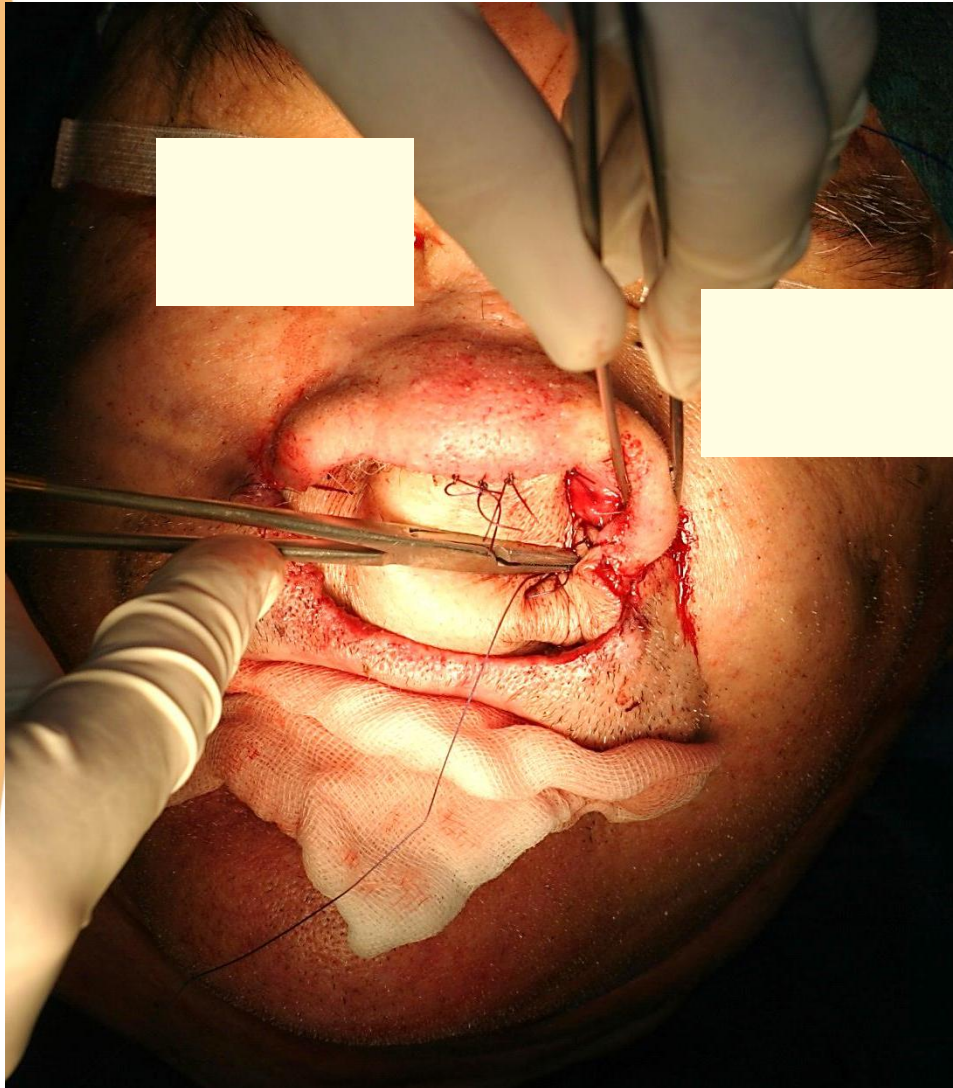
Sutures microchirurgicales



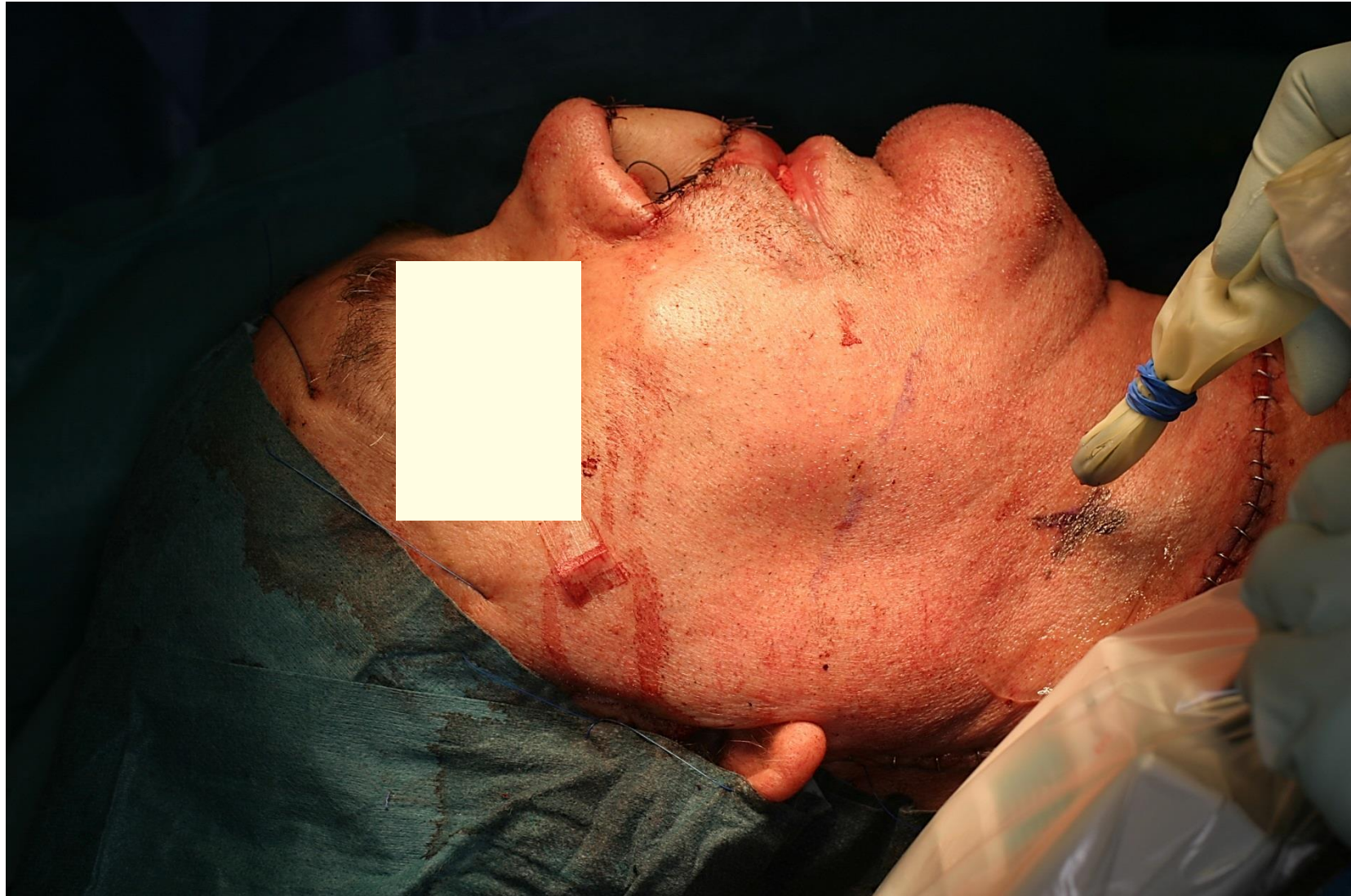Reconstruction pallatine

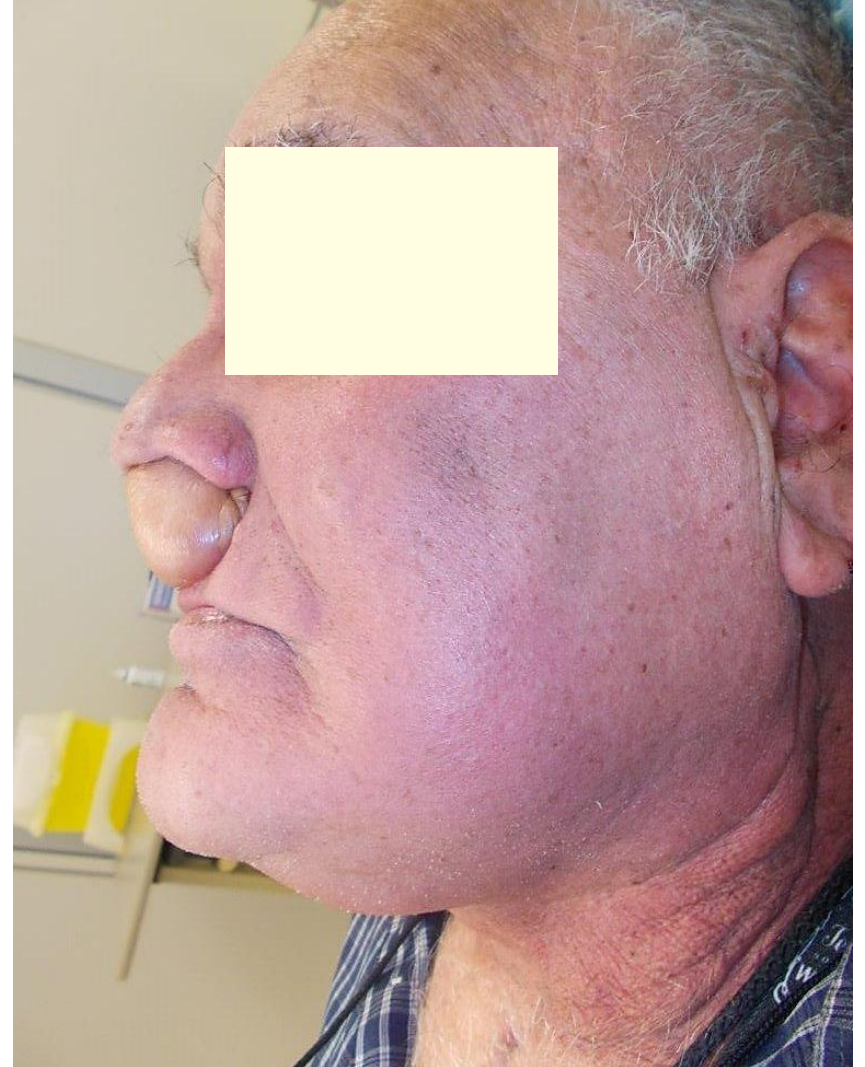
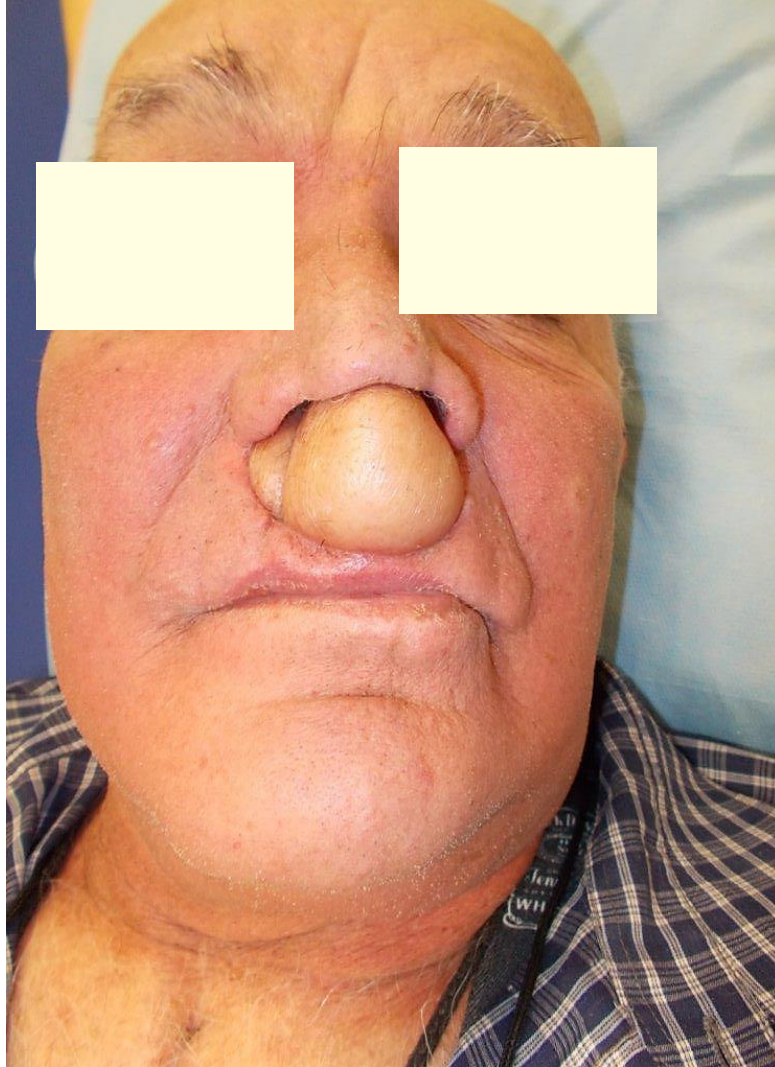
Reconstruction cloison nasale

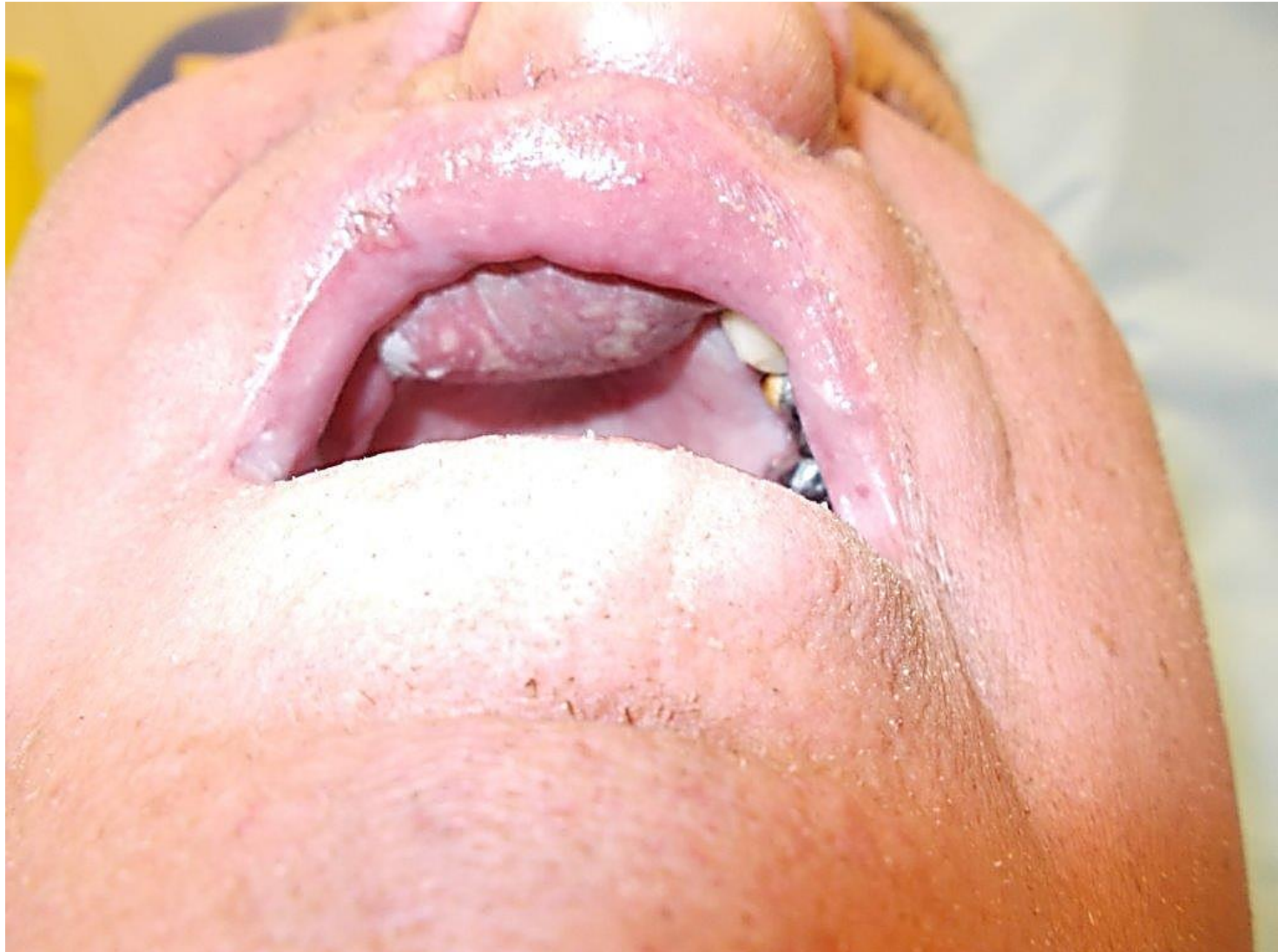

Surveillance artère par doppler



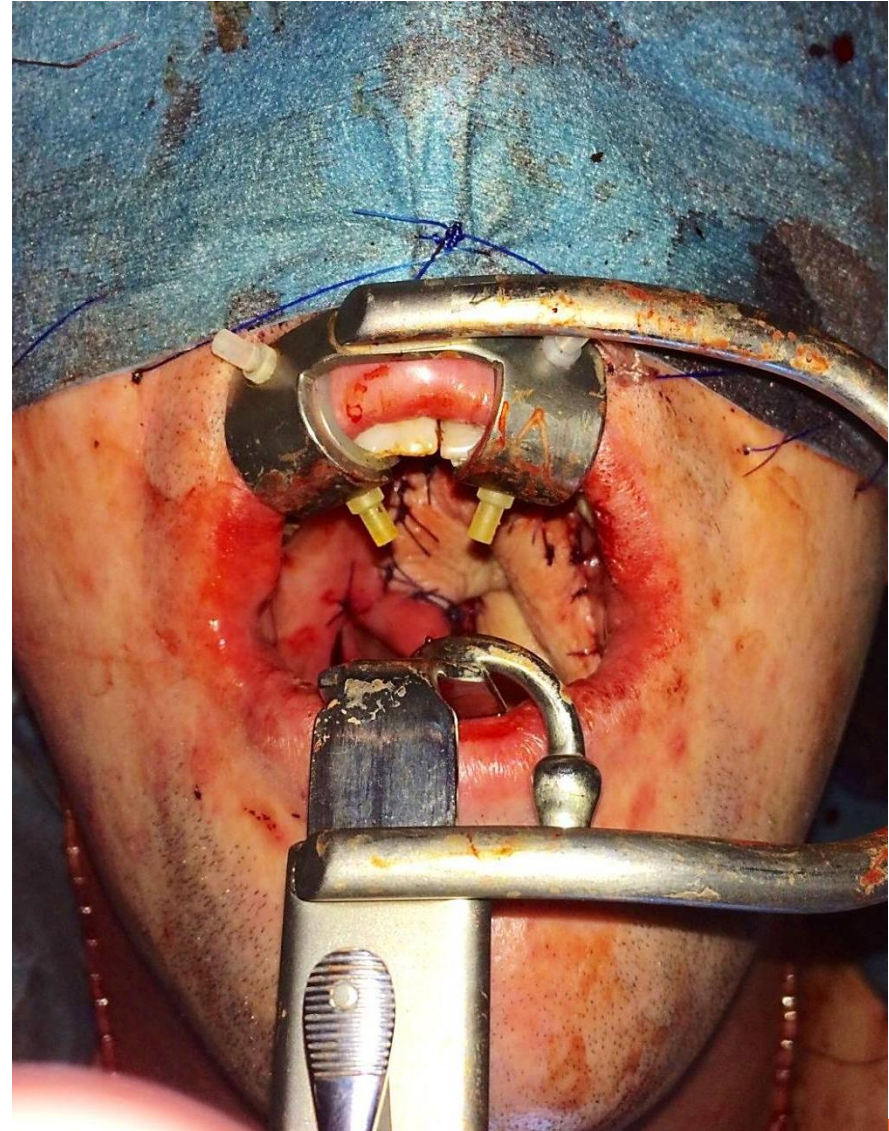
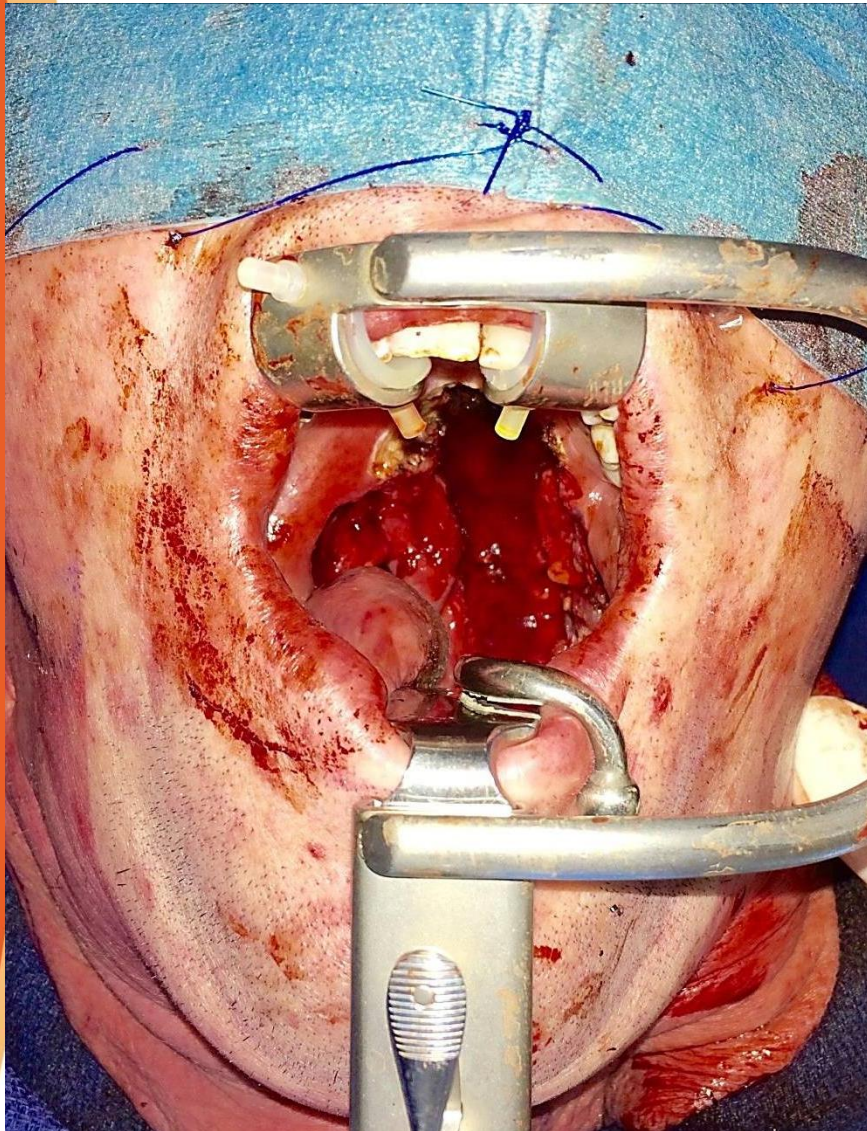


J 45 palais

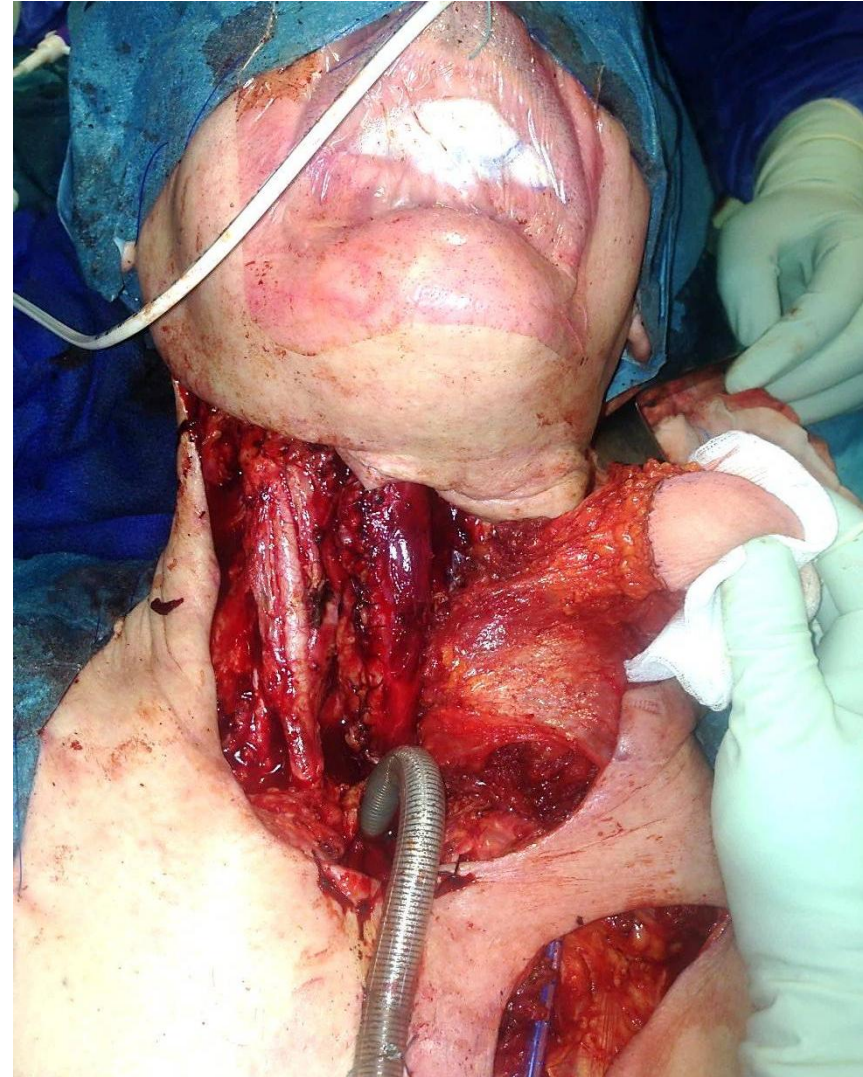
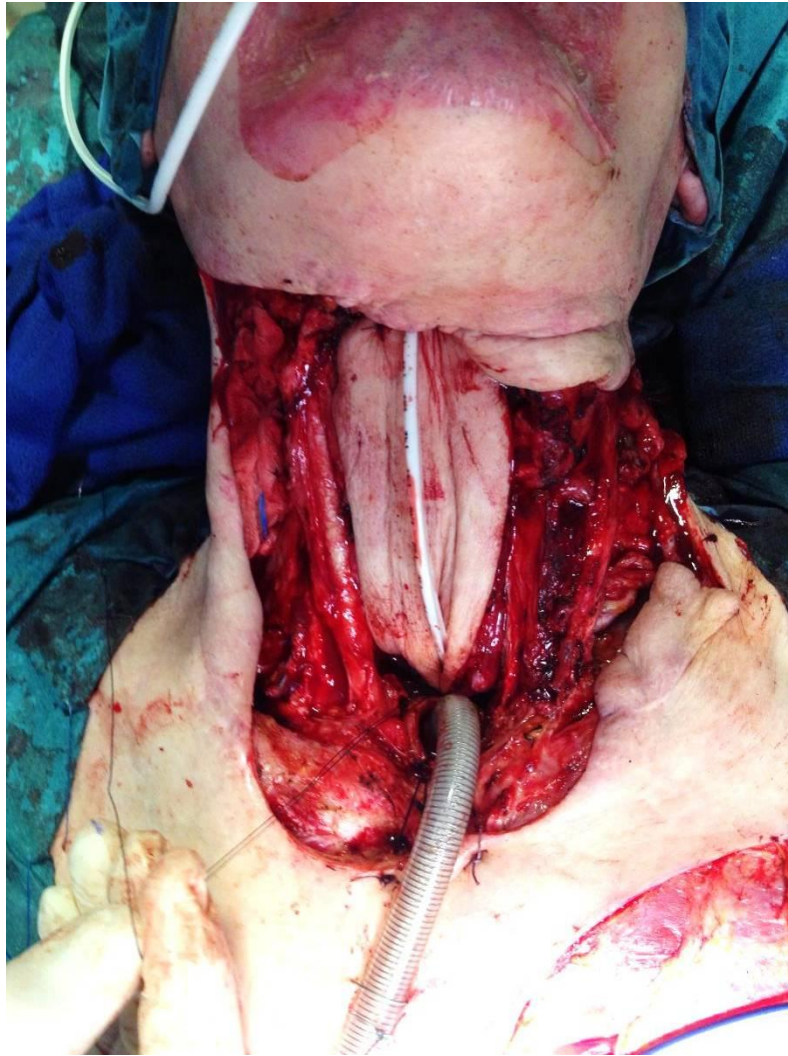




Voile palais + paroi pharyngée latérale + base de langue



Oesophage





Merci